

University of Louisville

ThinkIR: The University of Louisville's Institutional Repository

Electronic Theses and Dissertations

5-2014

Clinical efficacy of cross-sectional imaging compared with panoramic imaging and virtual 3D models for the assessment of dental implant placement.

Moiz Ahmad Khan 1987-
University of Louisville

Follow this and additional works at: <https://ir.library.louisville.edu/etd>



Part of the [Oral Biology and Oral Pathology Commons](#)

Recommended Citation

Khan, Moiz Ahmad 1987-, "Clinical efficacy of cross-sectional imaging compared with panoramic imaging and virtual 3D models for the assessment of dental implant placement." (2014). *Electronic Theses and Dissertations*. Paper 743.
<https://doi.org/10.18297/etd/743>

This Master's Thesis is brought to you for free and open access by ThinkIR: The University of Louisville's Institutional Repository. It has been accepted for inclusion in Electronic Theses and Dissertations by an authorized administrator of ThinkIR: The University of Louisville's Institutional Repository. This title appears here courtesy of the author, who has retained all other copyrights. For more information, please contact thinkir@louisville.edu.

CLINICAL EFFICACY OF CROSS-SECTIONAL IMAGING
COMPARED WITH PANORAMIC IMAGING AND VIRTUAL 3D
MODELS FOR THE ASSESSMENT OF DENTAL IMPLANT
PLACEMENT

By
Moiz Ahmad Khan

M.S, University of Louisville, 2014

A Thesis

Submitted to the School of Dentistry, University of Louisville

In Partial Fulfillment of the Requirements

For the Degree of
Master of Science

Department of Oral Biology

University of Louisville

Louisville, Kentucky

May, 2014

CLINICAL EFFICACY OF CROSS-SECTIONAL IMAGING COMPARED
WITH PANORAMIC IMAGING AND VIRTUAL 3D MODELS FOR THE
ASSESSMENT OF DENTAL IMPLANT PLACEMENT

By
Moiz Ahmad Khan
M.S, University of Louisville, 2014
A Thesis Approved on
14th April, 2014
By the following Thesis Committee:

Dr. Allan G. Farman, Thesis Co-Director

Dr. William C. Scarfe, Thesis Co-Director

Dr. Bryan T. Harris, Committe Member

Dr. Wei-Shao Lin, Committe Member

Dr. Eiad Elathamna, Committe Member

DEDICATION

This thesis is dedicated to my parents, Mr. Nisar Ahmed Khan and Dr. Nusrat Nisar.
Without their support, I wouldn't have been able to complete the research and masters.

ACKNOWLEDGEMENTS

Dr. Allan G Farman, Thesis Co-Director, for providing me the opportunity to work alongside him in the specialty of oral and maxillofacial radiology, and for his guidance and insight in this research which have made this project very enjoyable.

Dr. William C Scarfe, Thesis Co-Director, for assisting me in conducting research and gaining insight into the specialty of oral and maxillofacial radiology. Without his continued support and guidance, this research project would not have been possible. His willingness to help at all levels has been inspiring and his mentorship has truly been a rewarding experience.

Dr. Bryan T. Harris, Thesis Committee Member, for his support and for sharing his knowledge of clinical implant dentistry. His willingness to aid in my understanding of clinical implant dentistry, and his eagerness to teach is greatly appreciated.

Dr. Wei-Shao Lin, Thesis Committee Member, for his support and willingness to be a part of my research.

Dr. Eiad Elathamna for his continuous support and dedication to the research and willingness to play an active role in thesis.

ABSTRACT

CLINICAL EFFICACY OF CROSS-SECTIONAL IMAGING COMPARED WITH PANORAMIC IMAGING AND VIRTUAL 3D MODELS FOR THE ASSESSMENT OF DENTAL IMPLANT PLACEMENT.

Moiz Ahmad Khan

14th April, 2014

Introduction: This study compared the clinical efficacy of panoramic imaging and Cone Beam Computed Tomography (CBCT) in the optimal placement of virtual dental implants in the posterior edentulous bounded regions of the jaws. **Material and methods:** From a retrospective audit of patient records, fifty-two subjects were recruited with sixty-one dental implant sites in the maxilla and mandible. Physical measurements of the residual alveolar ridge were performed and consensus decisions of optimal implant length and bone graft necessity were obtained using reformatted panoramic alone (RP) or cross-sectional imaging (XS). **Results:** Horizontal restorative space measurements greater for RP ($p=0.001$). Shorter implants were chosen more often using CS than RP. Use of XS allowed planning that reduced the need for bone graft procedures by 50%. **Conclusion:** The use of cross-sectional imaging provides supplemental information that significantly influences virtual implant position and the need for bone grafting.

TABLE OF CONTENTS

DEDICATION.....	iii
ACKNOWLEDGEMENTS.....	iv
ABSTRACT.....	v
LIST OF TABLES.....	viii
LIST OF FIGURES.....	x
INTRODUCTION.....	1
The Need for Radiography Prior to Dental Implant Placement.....	3
Previous Research.....	3
Published Guidelines.....	4
Considerations for Optimal Placement of Dental Implants in the Edentulous Ridge...	11
Summary.....	12
HYPOTHESIS.....	13
Objectives.....	13
Null Hypothesis.....	14
MATERIALS AND METHODS.....	15
Hypothesis.....	15

Overall Research Design.....	15
Imaging.....	16
Subject Sample.....	17
Image Set Creation.....	19
Data Management and Statistical Methods.....	29
RESULTS.....	31
1) Subject Sample.....	31
2) Restorative and Alveolar space measurements.	33
3) Pan Implant relative measurements and length decision comparison.....	35
4) Measurements of Pan implant to adjacent anatomic structures.....	37
5) Exposure of threads of Implant.....	39
6) Decision of Grafting Choice.....	41
DISCUSSION.....	44
CONCLUSION.....	51
REFERENCES.....	52
CURRICULUM VITA.....	56

LIST OF TABLES

TABLE	PAGE
TABLE 1. COMPARISON OF DIFFERENT DENTAL IMAGING MODALITIES IN DENTAL IMPLANT BONE ASSESSMENT(SCARFE, <i>ET AL.</i> , 2012).....	2
TABLE 3. SAMPLE SIZE OF EDENTULOUS SPACES ACCORDING TO DENTAL ARCH.	32
TABLE 4. NUMBER OF MISSING TEETH IN EACH EDENTULOUS SPACE.....	32
TABLE 5. LOCATION OF EDENTULOUS SPACE ACCORDING TO MISSING TOOTH SITE.	32
TABLE 6. THE NUMBER OF MISSING TEETH IN EACH JAW.	33
TABLE 7. SAMPLE DESCRIPTION OF THE MAXIMUM HORIZONTAL CORONAL RESTORATIVE DISTANCE FOR EACH MODALITY.	34
TABLE 8. PAIRWISE CORRELATION BETWEEN MAXIMUM HORIZONTAL CORONAL RESTORATIVE DISTANCE FOR EACH MODALITY.	34
TABLE 9. PAIRED T-TEST BETWEEN MAXIMUM HORIZONTAL CORONAL RESTORATIVE DISTANCE FOR EACH MODALITY.	34
TABLE 10. SAMPLE DESCRIPTION OF THE MAXIMUM VERTICAL RESTORATIVE DISTANCE FOR EACH MODALITY.	35
TABLE 11. PAIRWISE CORRELATION BETWEEN MAXIMUM VERTICAL RESTORATIVE DISTANCE FOR EACH MODALITY.	35
TABLE 12. PAIRED T-TEST BETWEEN MAXIMUM VERTICAL RESTORATIVE DISTANCE FOR EACH MODALITY.	35
TABLE 13. COMPARATIVE CHOICE OF IMPLANT LENGTH DECISION FOR EACH MODALITY.	36
TABLE 14. COMPARATIVE CROSS-TABULATED ANALYSIS OF CHOICE OF IMPLANT LENGTH DECISION FOR EACH MODALITY.	37

TABLE 15. COMPARATIVE ANALYSIS OF CHOICE OF IMPLANT LENGTH DECISION FOR EACH MODALITY	37
TABLE 16. COMPARATIVE ANALYSIS OF VIRTUAL IMPLANT MEASUREMENTS WITH ADJACENT STRUCTURES FOR EACH MODALITY.....	38
TABLE 17. COMPARITIVE ANALYSIS OF ANGULATION OF VIRTUAL IMPLANT FOR EACH MODALITY.....	38
TABLE 18. COMPARATIVE ANALYSIS SHOWING NUMBER OF EXPOSED IMPLANT THREADS IN BUCCAL ASPECT FOR EACH MODALITY.	40
TABLE 19. COMPARATIVE ANALYSIS SHOWING NUMBER OF EXPOSED IMPLANT THREADS IN LINGUAL ASPECT FOR EACH MODALITY.....	40
TABLE 20. ASSESSED NEED FOR BONE GRAFTING USING EACH MODALITY.	42
TABLE 21. COMPARATIVE ANALYSIS OF BONE GRAFT NEED FOR EACH MODALITY.....	42
TABLE 22. COMPARATIVE CROSS-TABULATION SHOWING ASSESSED BONE GRAFT NEED FOR EACH MODALITY	42

LIST OF FIGURES

FIGURE	PAGE
FIGURE 1. THE GRAPHIC USER INTERFACE OF ANATOMAGE INVIVO 5.....	19
FIGURE 2. CLIPPED AXIAL VIRTUAL 3D MODEL REPLICATING AN IMPRESSION MODEL.	20
FIGURE 3. THE FOCAL TROUGH CREATED AT THE LEVEL OF CEJ OF MESIAL SURFACE OF RIGHT 2 ND MOLAR	20
FIGURE 4. THE ARCH SPLINE FORMED BY JOINING THE STANDARD REFERENCE POINTS FROM ANATOMIC STRUCTURES.	21
FIGURE 5. REFORMATTED PANORAMIC IMAGE GENERATED BY INVIVO SOFTWARE.....	22
FIGURE 6. MESIAL AND DISTAL RESTORATIVE SPACE MEASUREMENTS	22
FIGURE 7. AXIAL VIEW OF CROSS-SECTIONAL IMAGING MEASURING THE HORIZONTAL SPACE.....	23
FIGURE 8. CROSS-SECTIONAL IMAGE SHOWING THE VERTICAL RESTORATIVE SPACE AVAILABLE.	24
FIGURE 9. OPTIMAL DENTAL IMPLANT FROM STRAUMANN® PLACED IN PANORAMIC IMAGE.	25
FIGURE 10. CROPPED REFORMATTED PANORAMIC IMAGE SHOWING CALCULATION OF IMPLANT MEASUREMENTS RELATIVE TO ADJACENT ANATOMIC STRUCTURES.	26
FIGURE 11. DENTAL IMPLANT IN PLACE IN CLIPPED 3D VIRTUAL MODEL.....	26
FIGURE 12. MESIAL AND DISTAL DISTANCE TO ADJACENT TEETH AT IMPLANT PLATFORM.	27
FIGURE 13. ARCH SECTION SHOWING DISTANCE RELATIONSHIP AT IMPLANT APEX.....	28
FIGURE 14. CROSS-SECTION SHOWING MEASUREMENT DISTANCE OF PAN-IMPLANT FROM INFERIOR ALVEOLAR NERVE.	29

FIGURE 15. INCIDENCE OF MISSING TOOTH SITE IN UNIVERSAL TOOTH NUMBER.....	33
FIGURE 16. COMPARATIVE FREQUENCY OF CHOICE OF IMPLANT LENGTH (MM).....	36
FIGURE 17. FREQUENCY OF EXPOSED IMPLANT THREADS IN BUCCAL ASPECT FOR EACH MODALITY.	41
FIGURE 18. FREQUENCY OF EXPOSED IMPLANT THREADS IN LINGUAL ASPECT FOR EACH MODALITY.	41

CHAPTER 1

INTRODUCTION AND LITERATURE REVIEW

Dental implants are an increasingly used option for the replacement of missing teeth. The accurate placement of a dental implant in the jaw is facilitated by pre-treatment planning including the evaluation of the bone morphology such as quantity and topography, bone quality and assessment of the relationship of proposed implant to the anatomic structures such as nerves, blood vessels, adjacent tooth roots, the nasal floor and maxillary sinus (Saavedra-Abril, *et al.*, 2010). After a thorough history and clinical examination, panoramic imaging is the most often used imaging modality for radiographic assessment. Important considerations in choosing an appropriate imaging modality for implant site assessment for specific individuals include: numbers of potential implant sites to be examined, need of bone grafting, availability of imaging modalities, and radiation dose (Tyndall, *et al.*, 2000). Numerous authors have proposed surgically desirable parameters for fixture placement in regards to residual alveolar ridge. The most important goal of imaging is to enable translation of prosthetic planning to the surgical site (Frederiksen 1995, Garg, *et al.*, 1995, Almog, *et al.*, 1997, Ganz 2008, Rugani, *et al.*, 2009, Angelopoulos, *et al.*, 2011). Conventional two-dimensional (2D) radiographic techniques including periapical, lateral cephalometric and panoramic radiography, along with clinical examination and stone models of the dental arches have long been considered necessary for pre-treatment planning of dental implants (Harris, *et*

al., 2002).

Scarfe, *et al.* (Scarfe, *et al.*, 2012) provide a comparison of the relative clinical efficacy of different dental imaging modalities for the assessment of the residual alveolar ridge in different clinical procedures (Table 1).

Table 1. Comparison of different dental imaging modalities in Dental Implant Bone Assessment(Scarfe, *et al.*, 2012)

<i>Imaging Goal</i>	<i>Specific Objective</i>	<i>Cross-sectional</i>				
		<i>Intraoral</i>	<i>Extraoral</i>			
		<i>pa</i>	<i>Pan</i>	<i>Lat Ceph</i>	<i>Tomo</i>	<i>CBCT</i>
Morphology of the alveolar ridge	Vertical bone height	+++	++	+	+++	++++
	Horizontal bone width	-	-	-	+++	++++
	Edentulous saddle length	++	++	-	+++	++++
Orientation of the alveolar ridge	Bone Quality	+	++	-	++	+++
	Cross-sectional topography	-	-	+(anterior only)	+++	++++
Identify limitations of bone volume	Anatomy	+++	++	+	+++	++++
	Pathology	++	+++	+	++	+++
Correlate imaging findings to the prosthetic plan	Radiographic templates	++	++	+	++	++++
	Virtual implant/prosthesis	-	++	-	-	++++
	Computer-guided surgery	-	-	-	-	++++

pa, periapical radiography; pano, panoramic radiography; lat cephalometric radiography; Tomo, conventional tomography; CBCT; cone beam computed tomography; -, no/diminutive contribution; +, marginal/minimal contribution; ++, slight/mild contribution; +++, substantial/moderate contribution; +++++, significant/essential contribution.

The Need for Radiography Prior to Dental Implant Placement

Previous Research

Some authors suggest there are only specific clinical situations that may benefit from CBCT imaging and 2D imaging is usually adequate for most cases for pre-surgical site assessment and planning of dental implants in posterior region (Dave, *et al.*, 2012). Vazquez, *et al.*, (2008) suggest that panoramic radiographs in conjunction with periapical radiographs are satisfactorily for preoperative assessment for dental implants in molar regions where mandibular canal nerve injury and maxillary sinus perforation can occur (Vazquez, *et al.*, 2008). They contend that CBCT is an unnecessary radiation exposure to patients when “*the same clinical outcomes can be achieved with the panoramic radiograph at a lower radiation dose.*” In another study, Vazquez, *et al.*, (2011) found good comparison between calculated vertical magnification factor (MF) of panoramic radiographs and manufacturers listed vertical MF and concluded that panoramic radiography is a reliable modality for preoperative planning and selecting the posterior mandibular implant length (Vazquez, *et al.*, 2011). Further, Frei, *et al.*, (2004) concluded that cross sectional spiral tomography has little impact on treatment planning for implants in the mandibular premolar and molar regions. They suggested that critical information about mandibular canal could be obtained through clinical examination and panoramic radiographs alone (Frei, *et al.*, 2004).

Anecdotally those who have placed implants for several decades believe that their work has been successful even without the use of 3D imaging. However, often practitioner clinical success is often defined as patient satisfaction, rather than with esthetic, functional or other quantitative metrics. Another research suggests that direct

digital radiography and periapical radiography have accurate and faster diagnostic ability as compared to CBCT, which has “*lower image quality and slower decision making ability*” when detecting crestal radiolucency around dental implants(Sirin, *et al.*, 2012).

Published Guidelines

Several professional organizations have published varying opinions on the use of cross-sectional imaging for implant assessment in dentistry.

In 2002, (Harris, *et al.*, 2002) the European Association of Osseointegration (EAO) published their position paper on the role of cross-sectional imaging in relation to dental implant planning and updated it in 2012 (Harris, *et al.*, 2012). They identified four types of clinical situations that might potentially benefit from cross-sectional imaging for diagnosis and treatment planning:

- “1. When the clinical examination and conventional radiography have failed to adequately demonstrate relevant anatomical boundaries and the absence of pathology.*
- 2. When reference to such images can provide additional information that can help to minimize the risk of damage to important anatomical structures and which is not obtainable when using conventional radiographic techniques.*
- 3. In clinical borderline situations where there appears to be limited bone height and/or bone width available for successful implant treatment.*
- 4. Where implant positioning can be improved so that biomechanical, functional, and esthetic treatment results are optimized. The diagnostic information can be enhanced by use of radiographic templates, computer-*

assisted planning, and surgical guides.”

In 2012, The International Congress of Oral Implantologists (ICOI) published their position on the role of imaging for implant placement (Benavides, *et al.*, 2012). They state:

“The literature supports the use of CBCT in dental implant treatment planning particularly in regards to linear measurements, three-dimensional evaluation of alveolar ridge topography, proximity to vital anatomical structures, and fabrication of surgical guides.....CBCT should be considered as an imaging alternative in cases where the projected implant receptor or bone augmentation site(s) are suspect, and conventional radiography may not be able to assess the true regional three-dimensional anatomical presentation....”

In 2014, the International Team for Implantology (ITI) published a consensus statement on the use of CBCT in Implant Dentistry (Bornstein, *et al.*, 2014). They concluded:

“1. Current clinical practice guidelines for CBCT use in implant dentistry provide recommendations that are consensus-based or derived from non-standardized methodological approaches.

2. Published indications for CBCT use in implant dentistry vary from preoperative analysis to postoperative evaluation, including complications. However, a clinically significant benefit for CBCT imaging over conventional two-dimensional methods resulting in treatment plan alteration, improved implant success, survival rates, and reduced

complications has not been reported to date.

3. CBCT imaging exhibits a significantly lower radiation dose risk than conventional CT but higher than that of two-dimensional radiographic imaging. Different CBCT devices deliver a wide range of radiation doses. Substantial dose reduction can be achieved by using appropriate exposure parameters and reducing the field of view (FOV) to the actual region of interest (ROI).”

The American Academy of Oral and Maxillofacial Radiology published a position statement on selection criteria for the use of cross-sectional imaging in preoperative site assessment for dental implants(Tyndall, *et al.*, 2012). The summary points of this organization are:

“1. Establish the morphologic characteristics of the Residual Alveolar Ridge (RAR) such as vertical bone height, horizontal width, and edentulous saddle length. Moderate deficiencies may be corrected by augmentation procedures at the time of the osteotomy. However, severe deficiencies may need prior surgical procedures, such as ridge augmentation, and excessive alveolar bone may require pre-prosthetic or simultaneous alveoplasty.

2. Determine the orientation of the Residual Alveolar Ridge. The orientation and residual topography should be assessed to determine deviations of the RAR that compromise alignment, particularly in the mandible and anterior maxilla.

3. Identify local anatomic or pathologic conditions within the RAR

limiting implant placement. The clinician should be extremely familiar with internal anatomic features of both jaws. Failure to do so can compromise implant fixture placement or risk involvement of adjacent structures. Often these features are not easily identified or localized by clinical examination or conventional radiographic imaging. Anatomic anomalies may also be present. For example in Maxilla it includes nasopalatine fossa and canal and nasal fossa in anterior region and maxillary sinus floor in posterior region. In mandible this includes the mental foramen in the premolar region and the inferior alveolar nerve and the submandibular gland fossa in the posterior molars region.”

In 2000, The American Academy of Oral and Maxillofacial Radiology (AAOMR) published a position paper on the role of imaging in dental-implant treatment planning (Tyndall, *et al.*, 2000). They stated:

“After reviewing the current literature, the AAOMR recommends that some form of cross-sectional imaging be used for implant cases and that conventional cross-sectional tomography be the method of choice for gaining this information for most patients receiving implants.”

Since then, the introduction and increased use of maxillofacial CBCT has increased the availability of digital, cross-sectional imaging and expanded imaging clinical applications for dental-implant imaging. In their updated Position Statement in 2012, the AAOMR state (Tyndall, *et al.*, 2012):

“Specifically, the AAOMR recommends that cross-sectional imaging be considered for the assessment of most dental implant sites and that CBCT is the imaging method

of choice for gaining this information.”

In addition, the AAOMR provide eleven specific selection criteria recommendations on appropriate imaging (with particular relevance to CBCT) at each phase of dental-implant therapy. These are summarized in Table 2.

Collectively, the positions of these organizations on the use of dental imaging in implant dentistry are similar. However, slight differences exist between the positions of the organizations on the mechanics of the decision process. The AAOMR was clear to state that there is no perfect imaging available to practitioners, but went on to discuss major advantages of CBCT. Additionally, the AAOMR provided guidelines in a manner that was unlike the EAO and ICOI in that they looked at the implant placement phases and made recommendations on when to use, or not use, CBCT for implant dentistry. The three stages present by the AAOMR are initial exam, preoperative, and postoperative. It was interesting to note that the AAOMR specifically recommends not using a CBCT for initial examination, and to use panoramic and periapical radiographs for any information needed. This recommendation was not provided by either the EAO or ICOI.

In preoperative imaging AAOMR assessed benefits of CBCT in respect to the residual alveolar ridge (AR) and a prosthetic plan associated such as digital implant placement, and location of any major anatomical landmarks.

Table 2. Summary of AAOMR (2012) Selection Criteria Recommendations for the use of radiology in dental implantology with emphasis on cone beam computed tomography.

<i>Stage of implant therapy</i>	<i>Recommendation</i>
Initial examination	<p>Panoramic radiography should be used as the imaging modality of choice in the initial evaluation of the dental implant patient.</p> <p>Use intraoral periapical radiography to supplement the preliminary information from panoramic radiography.</p> <p>Do not use cross-sectional imaging, including CBCT, as an initial diagnostic imaging examination.</p>
Preoperative site specific imaging	<p>The radiographic examination of any potential implant site should include cross-sectional imaging orthogonal to the site of interest.</p> <p>CBCT should be considered as the imaging modality of choice for preoperative cross-sectional imaging of potential implant sites.</p> <p>CBCT should be considered when clinical conditions indicate a need for augmentation procedures or site development before placement of dental implants.</p> <p>CBCT imaging should be considered if bone reconstruction and augmentation procedures (e.g., ridge preservation or bone grafting) have been performed to treat bone volume deficiencies before implant placement.</p>
Postoperative imaging	<p>In the absence of clinical signs or symptoms, use intraoral periapical radiography for the postoperative assessment of implants. Panoramic radiographs may be indicated for more extensive implant therapy cases.</p> <p>Use cross-sectional imaging (particularly CBCT) immediately postoperatively only if the patient presents with implant mobility or altered sensation, especially if the fixture is in the posterior mandible.</p> <p>Do not use CBCT imaging for periodic review of clinically asymptomatic implants.</p> <p>Cross-sectional imaging, optimally CBCT, should be considered if implant retrieval is anticipated.</p>

Lastly, the AAOMR recommends CBCT for preoperative assessment if bone augmentation procedures are to be performed. Postoperatively, the recommendations were to only use the CBCT if clinical symptoms or implant mobility were seen in the

patient.

The EAO position provides generic guidelines on when it would be appropriate to use CBCT, specifically in any clinical situations where the practitioner had doubts about the amount of bone available in patients with different levels of edentulism. Additionally, their approach focused on achieving an image with radiation as low as reasonably achievable (ALARA). ALARA was also suggested in AAOMR as well as in ICOI guidelines. The EAO recommends the use of CBCT only if the clinical examination and conventional radiography fails to give the anatomical details. The ICOI suggests using CBCT scans to assess available bone, topography, anatomical structures, pathology, surgical guides, digital implant placement, and communication among all treating practitioners.

The ICOI suggestions were different to AAOMR in respect to support the use of CBCT on individualized patient needs basis; they contend that CBCT is not needed for all pre-surgical implant planning.

The ITI guidelines for use of CBCT in implant dentistry are broadly based on three considerations: 1) currently available use guidelines, 2) specific indication and contraindication for use, and 3) the associated relative radiation dose risk (Bornstein, *et al.*, 2014). Although the ITI takes a more affirmative stance for the use of CBCT in implant dentistry, the statement is clear in that decision should be based on any benefit outweighing the risks of radiation. The ITI also conclude that there is a lack of “*clear and statistically significant benefit of cross-sectional imaging using CBCT over conventional two dimensional imaging with respect to implant success and damage to inferior alveolar nerve or other vital neurovascular structure in jaws.*” The ITI strongly

recommended further research in this area to quantify the clinical efficacy of CBCT imaging.

Considerations for Optimal Placement of Dental Implants in the Edentulous Ridge

Each location in edentulous dental alveolar process presents with a specific set of considerations when planning the placement of dental implants. Our research focuses on posterior areas that present with important anatomical boundaries restricting the placement of the implant or may require alternate adjunctive therapies including bone grafting.

The residual alveolar ridge in the posterior maxillary region is restricted superiorly by the maxillary sinus floor. Assessment of the ridge height in this region is necessary to plan any pre-prosthetic surgical procedure such as bone grafting, sinus lift or alveoloplasty. The maxillary posterior region is also the least dense region of alveolar bone with highest implant failure rate (Kim, *et al.*, 2010). In the posterior mandible, the presence of the sub-mandibular fossa on the lingual aspect of the mandibular bone, inferior to the mylohyoid ridge, is an important anatomic structure to assess in order to avoid bony fenestration or dehiscence with dental implant placement. The presence of the inferior alveolar canal (IAC) containing the inferior alveolar nerve and vessels is also an important intra-medullary boundary to implant placement. Further anteriorly in the premolar region this structure exits through the buccal cortical bone through the mental foramen and may be associated intra-medullary as an “anterior loop” configuration. The location of these structures is critical to determine to prevent paresthesia, dysaesthesia or anesthesia associated with involvement of the associated neurovasculature.

While there are various subjective and objective definitions, the “clinical success” of

a dental implant invariably depends on optimal positioning within the available residual (or graft augmented) alveolar ridge (RAR) in an edentulous region to restore function with acceptable esthetics (Esposito, *et al.*, 2011). The overall dental implant failure rate is approximately 3% in all dental sites in upper and lower jaws (Lee, *et al.*, 2011, Babbush, *et al.*, 2012). The replacement of missing teeth by prosthetically restored implants in the molar region is particularly challenging as this region has greater occlusal forces than the anterior region of the mouth (Rossetti, *et al.*, 2010) and therefore the amount of bone volume for fixture placement and restorative space is critical. Numerous authors describe varying optimal criteria for dental implant fixture placement depending on the site and technique used (Searson, *et al.*, 1997, Buchter, *et al.*, 2006, Levin 2011, Oliver 2012).

In the bucco-lingual/palatal dimension, it is desirable that there should be at least 1.0mm of alveolar bone width on either side of the dental implant (Vera, *et al.*, 2012). It is also preferable to have at least 1.0mm of bone separating the dental implant fixture from any adjacent anatomic structures (e.g. mandibular canal, maxillary sinus, surrounding tooth root structures (Krennmair, *et al.*, 2003, Misch, *et al.*, 2008). Also in the mesio-distal aspect, it is preferable to have 1.5-2.0mm separating the implant fixture from any adjacent tooth root (Greenstein, *et al.*, 2006).

Summary

There is a lack of clear evidence from published research on the clinical efficacy of CBCT cross-sectional imaging. Therefore, the purpose of this study is to determine if assessments of restorative space (for coronal restoration) and bone volume (for implant fixture placement) available in the residual alveolar ridge in the maxillary and mandibular posterior edentulous regions, when made according to optimal implant selection and placement criteria, varies depending on the availability of CBCT cross-sectional imaging.

CHAPTER 2

HYPOTHESES

Objectives

The aims of this research are:

1. To quantitatively measure and compare the amount of vertical and horizontal restorative space available in the residual alveolar ridge at specific sites in posterior partially edentulous regions made using reformatted panoramic images alone to CBCT cross-sectional images.
2. To compare the distance relationship of dental implant placed using reformatted panoramic images and virtual models alone to that measured on CBCT cross-sectional images.
3. To compare the differences in choice of dental implant length based on using reformatted panoramic images and virtual models alone to CBCT cross-sectional images.
4. To compare the difference in the number of threads exposed of dental implants when placed using reformatted panoramic images and virtual models alone to CBCT cross-sectional images.
5. To compare the difference in angulation of dental implants when placed using reformatted panoramic images and virtual models alone to CBCT cross-sectional images.

6. To compare the treatment decision regarding the need for adjunctive surgical procedures when dental implants are placed using reformatted panoramic images and virtual models alone to CBCT cross-sectional images.

Null Hypothesis

It is hypothesized that:

1. There is no difference quantitatively in the amount of vertical and horizontal restorative space available in the residual alveolar ridge at specific sites in posterior partially edentulous regions made using reformatted panoramic images alone to CBCT cross-sectional images.
2. There is no difference in distance relationship of dental implant placed using reformatted panoramic images and virtual models alone to that measured on CBCT cross-sectional images.
3. There is no difference in choice of dental implant length based on using reformatted panoramic images and virtual models alone to CBCT cross-sectional images.
4. There is no difference in the number of threads exposed of dental implants when placed using reformatted panoramic images and virtual models alone to CBCT cross-sectional images.
5. There is no difference in angulation of dental implants when placed using reformatted panoramic images and virtual models alone to CBCT cross-sectional images.
6. There is no difference in the treatment decision regarding the need for adjunctive surgical procedures when dental implants in each modality.

CHAPTER 3

MATERIALS AND METHODS

Hypothesis

There is difference between measurements of bone volume of the residual alveolar ridge and restorative space available in the posterior edentulous regions of the maxilla and mandible between reformatted panoramic imaging and CBCT cross-sectional imaging. Differences are present between measurements obtained from reformatted panoramic imaging alone and CBCT cross-sectional imaging between the dental implant and adjacent anatomic structures. There is a difference in choice of dental implant dimensions when using reformatted panoramic imaging alone and CBCT cross-sectional imaging. There are differences in the number of exposed dental implant threads and angulation of dental implants between reformatted panoramic imaging alone and CBCT cross-sectional imaging. There is also a difference in treatment decision in regard to the need for supplemental pre-prosthetic surgical procedures comparing the use of reformatted panoramic imaging and virtual models alone and CBCT cross-sectional imaging.

Overall Research Design

This investigation is an observational retrospective study based on the anatomic characteristics of the residual alveolar ridge (RAR) in the edentulous 1st molar and premolar region in both dental jaws. A retrospective audit of cone beam computed

tomography (CBCT) radiographic report database of patients referred for dental imaging to assess the status of the RAR prior to implant fixture placement was performed. Using implant planning software, measurements were made of the available alveolar bone and restorative space on reformatted panoramic images and cross-sectional imaging separately, both generated from the CBCT data. A virtual dental implant of standard appropriate dimensions appropriate was placed at the edentulous site on a reformatted panoramic image and the position verified using a three-dimensional volumetric surface rendering – a virtual model replicating a stone study model. The dental implant position relative to adjacent anatomic structures, choice of implant dimensions and need for supplemental pre-prosthetic surgical procedures was verified by consensus of three Prosthodontists and recorded by the PI. The same procedure was used using CBCT based cross-sectional imaging one month later. Comparisons of measurements, implant dimensions and treatment decisions were compared between modalities used. Intra-rater variability of the single observer (PI) was determined by repeating the implant placement procedure on a reformatted panoramic image one month later. Frequency tabulations and measurement means and standard deviations were calculated, analyzed and compared to accepted implant placement criteria.

Imaging

Institutional Review Board (IRB) approval was granted on December 5th 2012 (IRB # 12.0534). The initial sample consisted of all available CBCT radiographic reports from installation of the equipment (May 13, 2004) to a convenience date (31st September, 2012). The database consisted of patients referred either internally from within the University of Louisville School of Dentistry or externally from practitioners in private

dental practice for CBCT imaging. This referral service is operated as the faculty private practice by Drs. Allan G. Farman and William C. Scarfe, both being professors in the Dept. of Surgical/Hospital Dentistry at the University of Louisville School of Dentistry. Both are board certified and licensed specialists in Oral and Maxillofacial Radiology.

All CBCT images were acquired using an i-CAT™ Classic CBCT unit (Imaging Sciences International, Hatfield, PA, USA). The device was operated at 1-3mA and 120 kV using a high frequency, constant potential, fixed-anode with a nominal focal spot size of 0.5mm. Each patient was positioned into the device supported by the constructed plastic head holder. The hard tissue chin of each patient was inserted into the chin holder and vertical and horizontal laser lights on the device used to position the head. The head was oriented such that the mid-sagittal was perpendicular to the floor and the horizontal laser reference was along an imaginary line at the intersection of the porion–orbitale (Frankfort Horizontal). The imaging protocol used a nominal resolution of 0.4 mm before January 2010 and 0.3mm thereafter. Scans were performed at one of three volume sizes; 13.2 cm, 8 cm or 6 cm heights.

Subject Sample

This study involved a retrospective audit of CBCT written radiographic report records within a database. The database was located on a secure server with limited access within Radiology and Imaging Sciences, Dept. of Surgical/Hospital Dentistry at the University of Louisville, School of Dentistry, Louisville, Kentucky.

4,014 radiographic reports were available for audit within the designated time-frame. The following specific data fields were exported from these records to a spreadsheet (Excel, Microsoft Corp., Redmond, WA):

1. *Date.* Date the CBCT scan was performed.
2. *Age.* Age of the potential subject at the time of the CBCT procedure.
Recorded in whole years.
3. *Type of Scan Performed:* Maxilla only, mandible only, maxilla and mandible (8cm), Maxilla and mandible (13.2 cm)
4. *Reason for referral.* Categorical structured text categorizing the reason that the patient was referred for a CBCT scan. Categories included Implant CBCT, Pathology CBCT, Fracture CBCT, TMJ CBCT, TMJ Tomography, Trauma CBCT, Cleft Lip/Palate, Ortho CBCT, Third Molar CBCT, Cephalometric, Sleep Apnea, Dento/Craniofacial, Impaction CBCT, Surgical follow up - plates/graft, Surgical follow up – recurrence, Surgical follow up – trauma, Consultation
5. *Radiologic findings.* Narrative text data describing any modifications to the scan procedure and describing the imaging features of the condition.
6. *Radiologic Impression.* Narrative text data summarizing the primary and incidental or secondary imaging findings.

Patient waivers were not necessary, as all Protected Health Information (PHI) was stripped from the data set collected for analysis.

The reports were screened to meet the following inclusion and exclusion criteria:

- a. Missing teeth not more than two in a single quadrant of a arch (1st premolar, 2nd premolar and 1st molar);
- b. No pathologic lesion in the posterior maxilla and mandible
- c. No history of bone grafting at the implant site, and

d. Absence of systemic disease, infections or illnesses.

A total of 52 subjects were selected having one or multiple dental implant placement sites available for assessment.

Image Set Creation

The images were viewed in Invivo Dental Application (Version 5.2.4, Anatomage, San Jose, CA). This software version had primarily 10 Tab options to work with namely Section, Volume Render, Arch Section, Implant, TMJ, Super Pano, Super Ceph, Superimposition, Gallery and Model (Fig. 1).

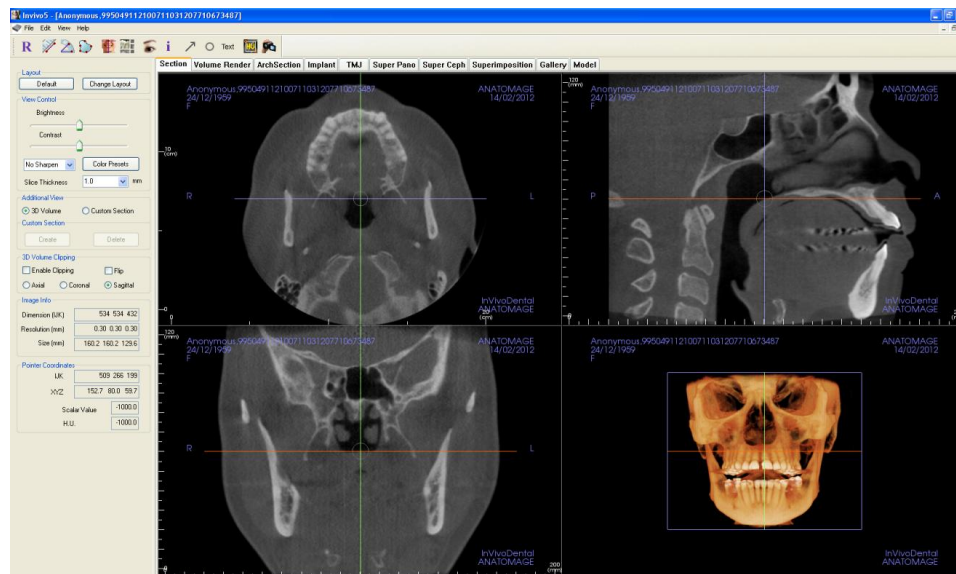


Figure 1. The graphic user interface of Anatomage InVivo 5.

The images were assessed in reformatted panoramic images and virtual models with clipped in axial dimensions to hide the information of mental foramen (Fig. 2).

From the axial view, the focal plane was created by using the arch spline tool formed by joining points on right side of the most distal point on ramus of mandible/most distal point on maxilla, the center of 2nd molar, the center of canine, the center point between central incisors and the same points on the left side (Fig. 4).

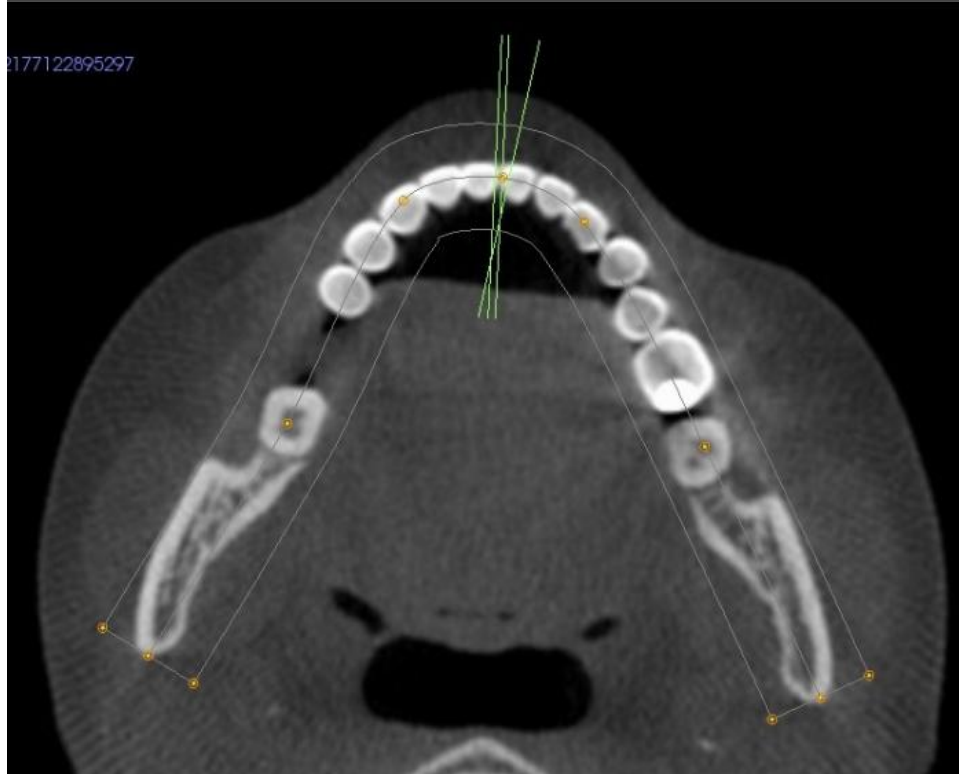


Figure 4. The Arch spline formed by joining the standard reference points from anatomic structures.

After the construction of focal trough, a reformatted panoramic image was generated by the software with default, standard thickness of 15mm in the super-pano section (Fig. 5).

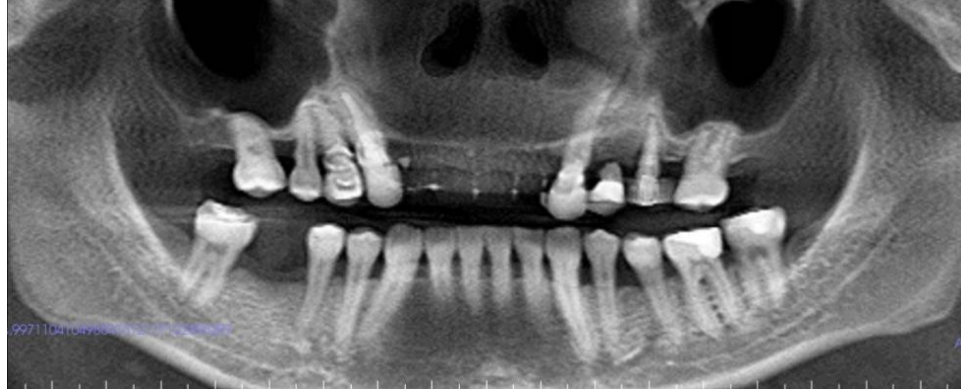

Figure 5. Reformatted Panoramic Image generated by Invivo software.

The restorative space and alveolar ridge measurements were calculated in both panoramic and cross-sectional imaging according to standardized reproducible criteria Fig. 6 (Sirin, *et al.*, 2012, Pittayapat, *et al.*, 2013).

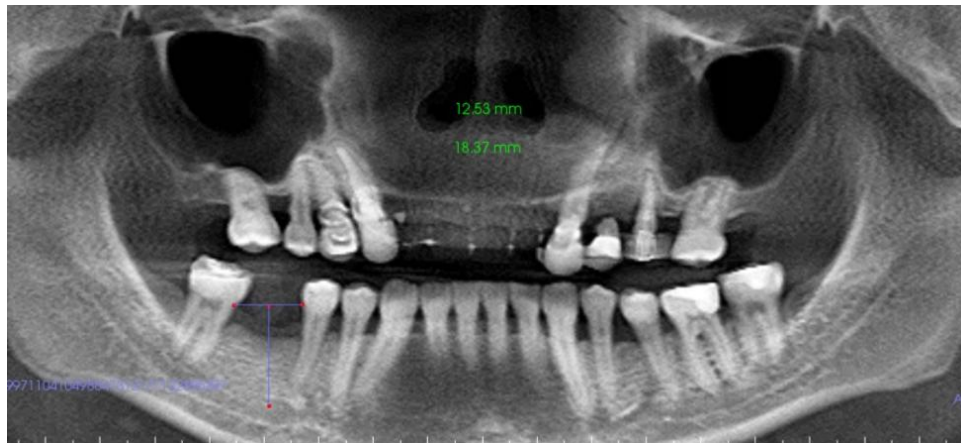


Figure 6. Mesial and Distal Restorative Space Measurements

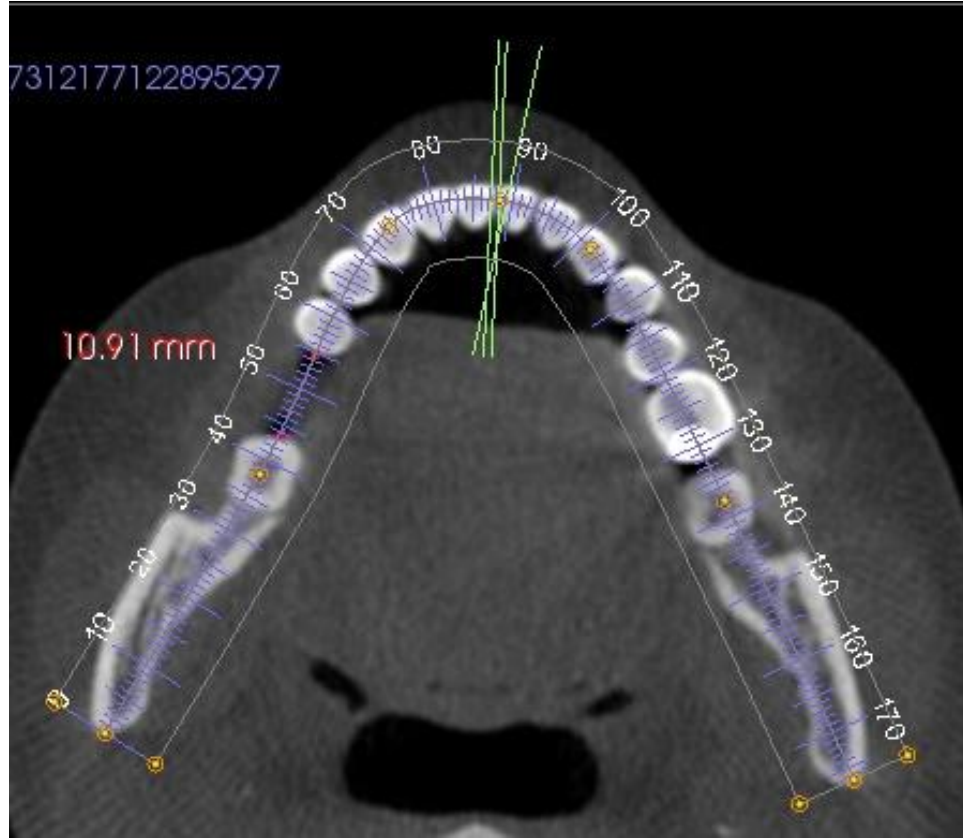


Figure 7. Axial view of cross-sectional imaging measuring the horizontal space.

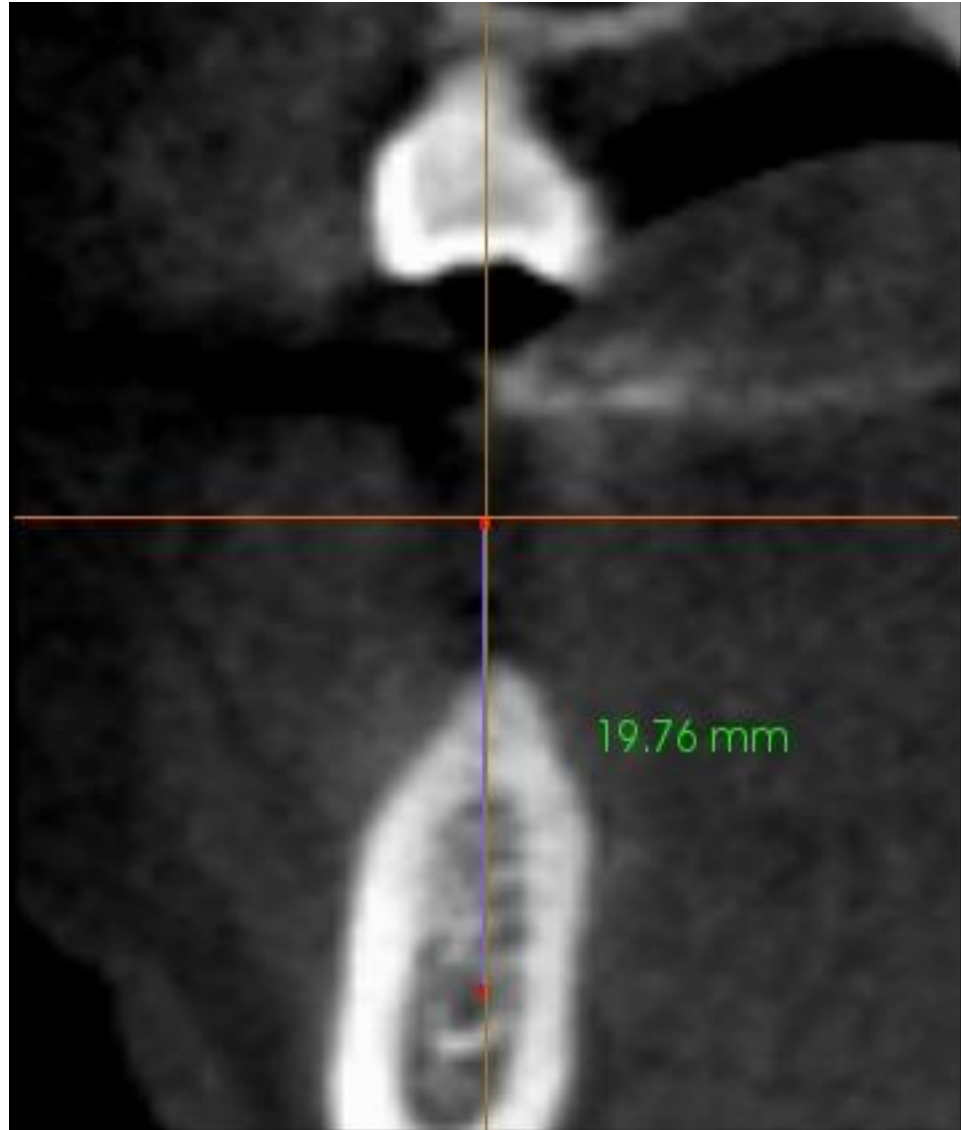

Figure 8. Cross-sectional image showing the vertical restorative space available.

A virtual dental implant was placed on the reformatted panoramic image and virtual models, simulating the diagnostic implant planning procedure most often used by practitioners without access to cross-sectional imaging. The virtual model was clipped axially to obscure the location of the mental foramen (as it is not visible in the real impression model). To ensure implant choice uniformity, choice of virtual implants was restricted to Straumann® Bone Level Regular CrossFit® designs. Molars and premolars

were replaced with bone-level implants of diameter 4.80 mm 4.10 mm respectively. Three implant lengths were available: 8 mm, 10 mm and 12 mm. The implants were placed using ITI implant treatment guide (Fig. 9).

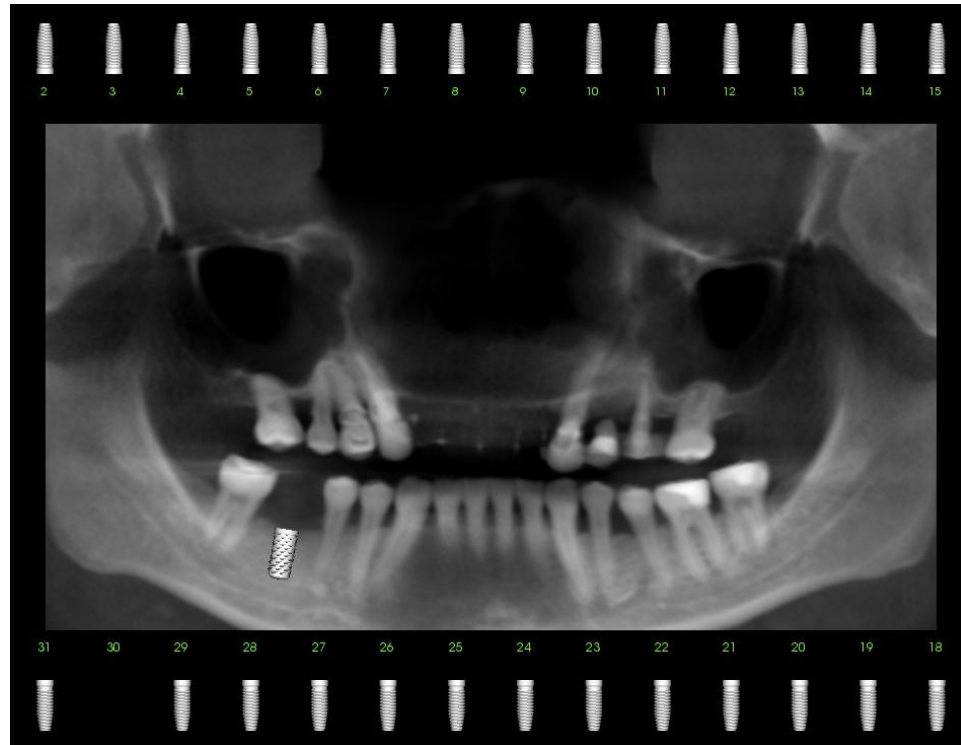


Figure 9. Optimal dental implant from Straumann® placed in Panoramic Image.

The investigator placing the implants was a dental practitioner with knowledge of ITI guidelines for placing dental implants. The implant position was reviewed, assessed and verified by three Prosthodontists. Consensus between the Prosthodontists was reached on the position of the dental implant using panoramic images and virtual models alone. The implant dimensions in buccal, lingual, mesial and distal directions relative to dental implant were measured on panoramic images (Fig. 10) and the virtual 3D model was then inspected to identify assessed for any bony perforation or fenestration (Fig. 11).

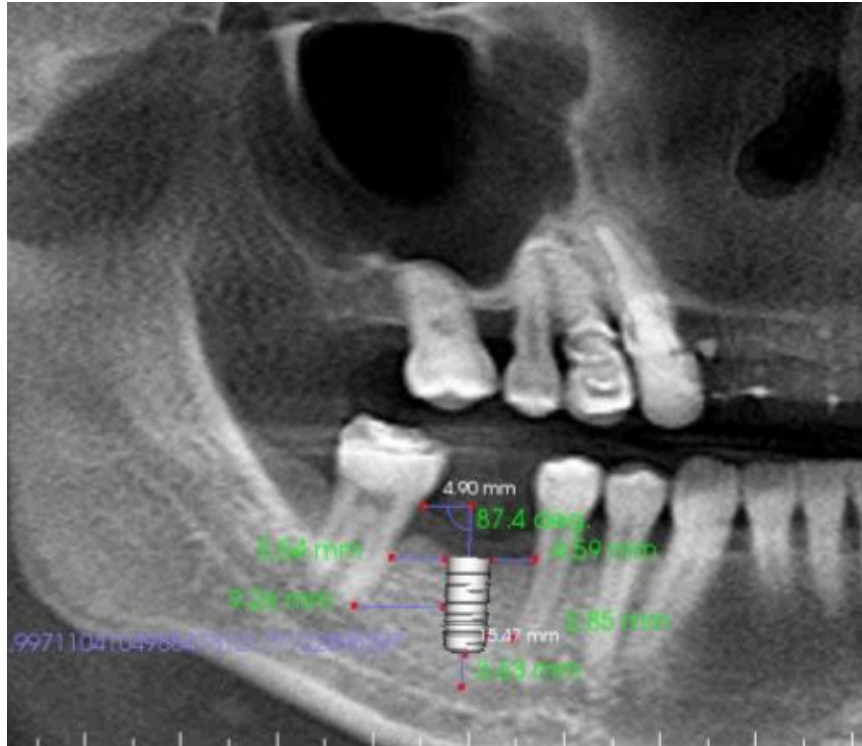


Figure 10. Cropped reformatted panoramic image showing calculation of implant measurements relative to adjacent anatomic structures.

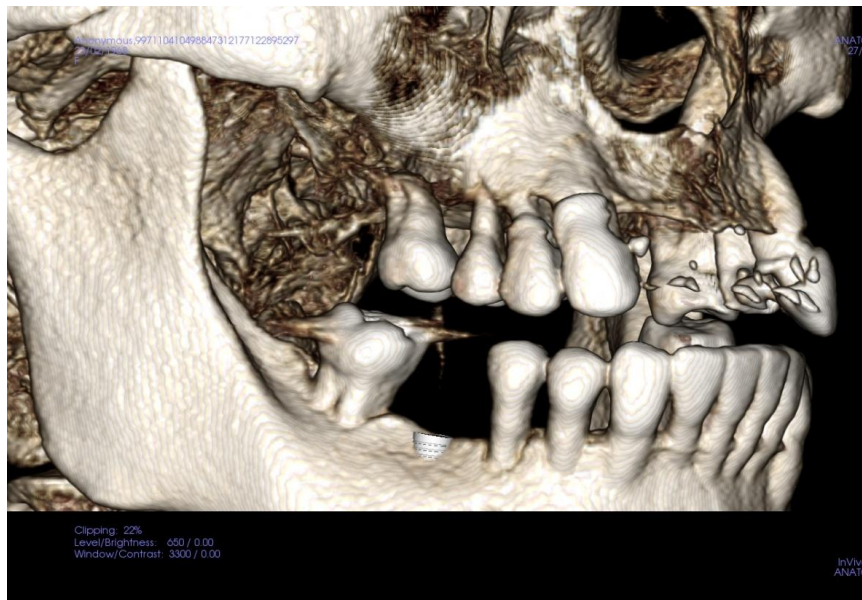


Figure 11. Dental implant in place in clipped 3D virtual model.

For cross-sectional imaging the same procedure and measurements were repeated

(Figs. 12, 13 and 14).

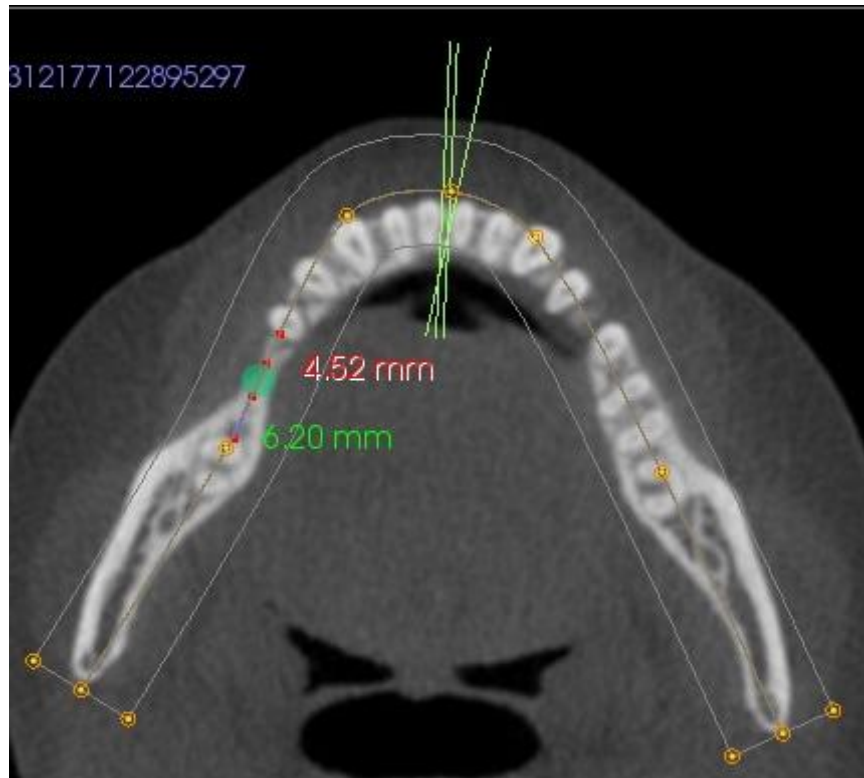


Figure 12. Mesial and Distal distance to adjacent teeth at implant platform.

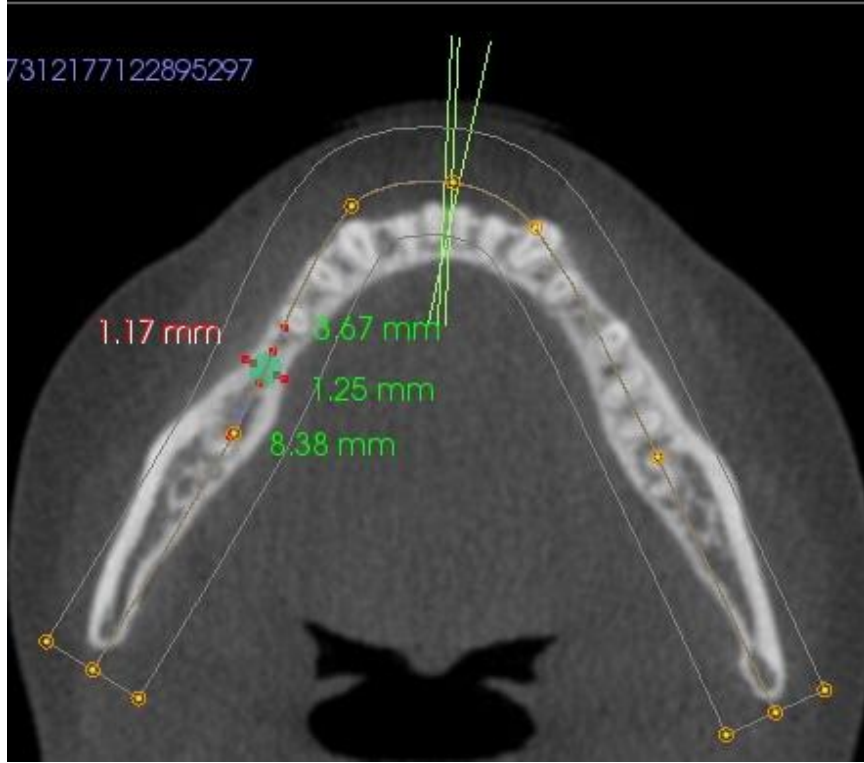


Figure 13. Arch section showing distance relationship at implant apex.

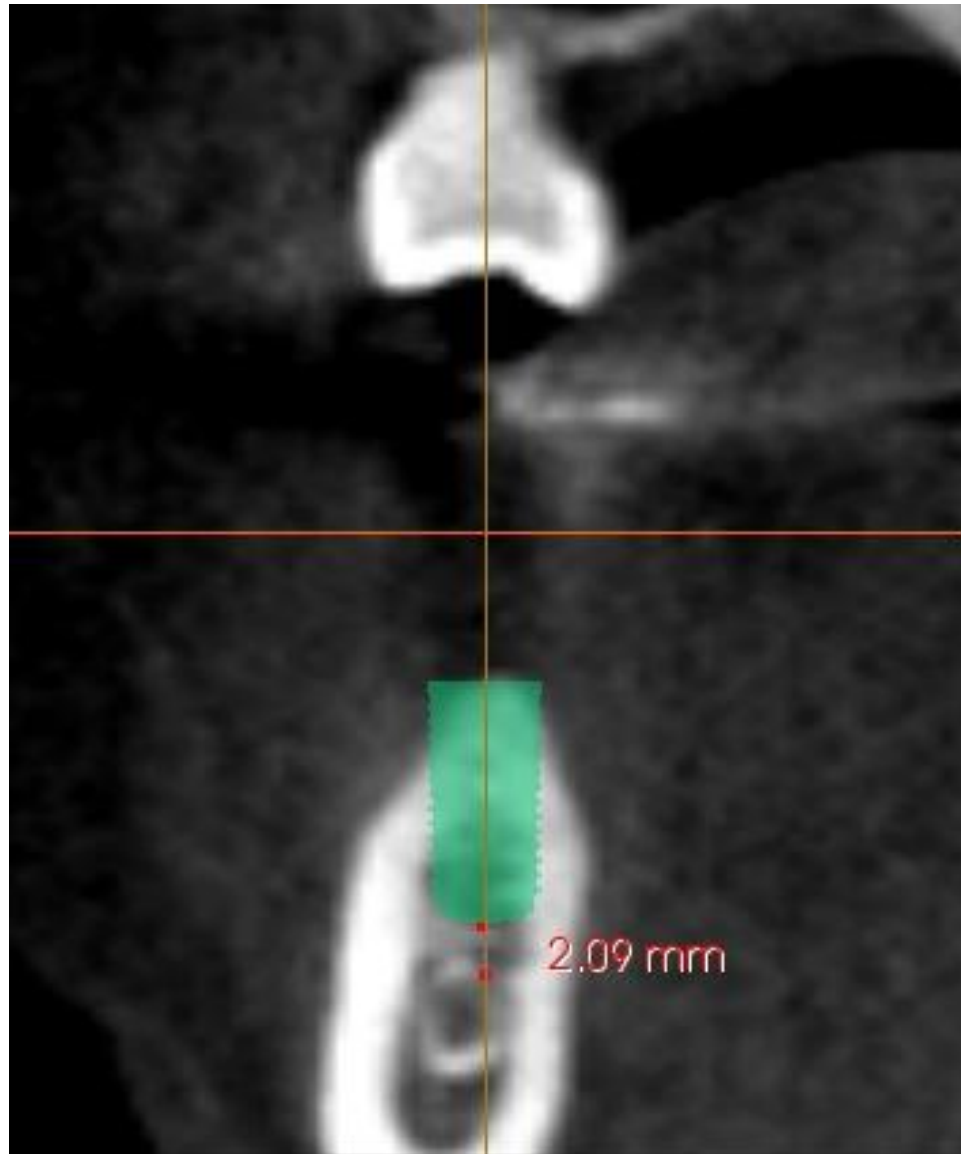

Figure 14. Cross-Section showing measurement distance of Pan-Implant from Inferior Alveolar Nerve.

Intra-rater variability of the observer (PI) was calculated for replicate measurements and decisions using both in panoramic imaging and virtual model alone and cross-sectional imaging placing a second implant at the site after a gap of one (1) month.

Data Management and Statistical Methods

The demographic variables included arch, universal missing tooth number, number of

missing teeth and age. Frequency distributions were generated and, when appropriate, means \pm s.d. calculated.

The data was c into the following areas for interpretation, comparison between modalities and analysis;

- (a) Measurements of restorative space and alveolar ridge dimension. Differences between modalities were determined using the Paired t-Test.
- (b) Implant length choice (8mm, 10mm and 12mm). Differences between modalities were determined using the Chi-Square test.
- (c) Relative measurements from the position of the pan implant to adjacent anatomic structures. Differences between modalities were determined using the Paired t-Test.
- (d) Number of exposed threads of the virtual implant on the buccal and lingual aspects. Differences between modalities were determined using the Paired t-Test.
- (e) Need for supplemental pre-prosthetic surgical procedure. Differences between modalities were determined using the Chi-Square test.

CHAPTER 4

RESULTS

The results for this study are provided in six sections. The first section describes the demographics of the sample. The second section analyses the difference in measurements of restorative space and alveolar ridge dimensions in both modalities. The third section provides Implant length choice differences between modalities. The fourth part provides relative measurements differences from the position of the pan implant between modalities. The fifth part provides the differences in number of exposed threads of the virtual implant on the buccal and lingual aspects between modalities. The sixth part provides the differences in need for supplemental pre-prosthetic surgical procedure between modalities.

1) Subject Sample

The radiographic interpretive records of 4,014 subjects were audited. Fifty two ($n_1=52$) subjects were identified with sixty one ($n_2=61$) dental implant sites satisfying the inclusion criteria for the study. Tables 3-6 and Figure 15 summarize the demographics of the implant sites. We had 76.9% of total cases in Mandible with majority of cases missing only one tooth for implant placement (82.7%). The most common teeth missing were 1st molars in mandible [universal tooth number 19 (38.5%) and 30 (23.1%)].

Table 3. Sample Size of edentulous spaces according to dental arch.

<i>Arch</i>	<i>Frequency</i>	<i>Percentage</i>
Maxilla	12	23.1
Mandible	40	76.9
Total	52	100.0

Table 4. Number of missing teeth in each edentulous space.

<i>Number of Missing teeth in the Edentulous Space</i>	<i>Frequency</i>	<i>Percentage</i>
1	43	82.7
2	9	17.3
Total	52	100.0

Table 5. Location of edentulous space according to missing tooth site.

<i>Location of Edentulous Space (Tooth site)*</i>	<i>Frequency</i>
3	2
4	1
5	1
12	1
13	1
14	6
19	20
20	2
29	6
30	12
Total	52

*Universal tooth numbering system

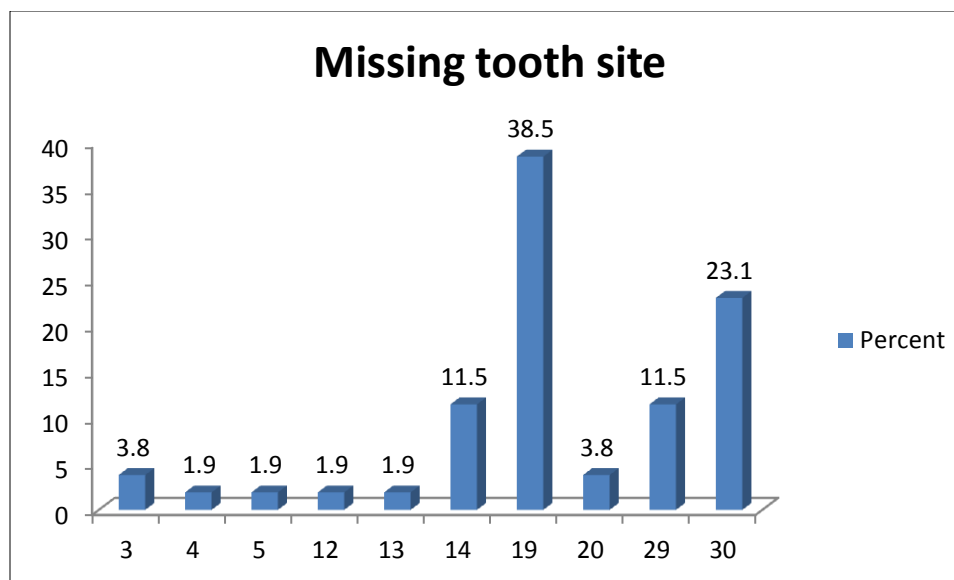


Figure 15. Incidence of Missing tooth site in Universal Tooth Number

Table 6. The number of missing teeth in each jaw.

<i>Jaw Arch</i>	<i>Number of Missing teeth</i>		<i>Total</i>
	1	2	
Maxilla	12	0	12
Mandible	31	9	40
Total	43	9	52

2) Restorative and Alveolar space measurements.

Tables 7-9 provide the comparative analysis of the maximum horizontal coronal restorative distance in millimeters between each modality. The mean horizontal coronal restorative distance was statistically greater ($0.45 \pm 0.13 \text{mm}$) in reformatted panoramic imaging than in axial CBCT imaging. Pair-wise correlation shows a strong ($C=+0.95$) significant ($p=0.001$) linear correlation between the two variables. The paired t-Test shows a significant difference in the measurements done in two modalities ($p=0.01$).

Tables 10-12 provide the comparative analysis of the maximum vertical restorative distance measured in reformatted panoramic imaging and axial CBCT imaging. There was a statistically greater mean vertical distance (0.42 ± 0.41 mm) measured by reformatted panoramic imaging than axial CBCT imaging. There was a strong ($C = +0.85$) significant ($p = 0.001$) linear correlation between the two variables, but the paired t-Test showed no statistically significant difference ($p = 0.21$).

Table 7. Sample description of the maximum horizontal coronal restorative distance for each modality.

<i>Modality</i>	<i>Mean</i>	<i>N</i>	<i>SD</i>	<i>SE</i>
Reformatted panoramic image	12.84	52	3.78	0.52
Axial CBCT image	12.39	52	3.91	0.54

SD, standard deviation; SE, standard error

Table 8. Pairwise correlation between maximum horizontal coronal restorative distance for each modality.

<i>Pairwise comparison</i>	<i>N</i>	<i>Correlation</i>	<i>Sig.</i>
Reformatted panoramic image Axial CBCT	52	0.95	0.001

Table 9. Paired t-Test between maximum horizontal coronal restorative distance for each modality.

<i>Pairwise comparison</i>	<i>95% Confidence Interval</i>		<i>Significance</i>	
	<i>Lower</i>	<i>Upper</i>	<i>t</i>	<i>p value</i>
Reformatted panoramic image Axial CBCT	0.11	0.78	2.656	0.01

Table 10. Sample description of the maximum vertical restorative distance for each modality.

<i>Modality</i>	<i>Mean</i>	<i>N</i>	<i>SD</i>	<i>SE</i>
Reformatted panoramic image	17.42	52	3.78	0.52
Para-Sagittal CBCT	17.00	52	4.19	0.58

SD, standard deviation; SE, standard error

Table 11. Pairwise correlation between maximum vertical restorative distance for each modality.

<i>Pairwise comparison</i>	<i>N</i>	<i>Correlation</i>	<i>Sig.</i>
Reformatted panoramic image Para-Sagittal CBCT	52	0.83	0.001

Table 12. Paired t-Test between maximum vertical restorative distance for each modality.

<i>Pairwise comparison</i>	<i>95% Confidence Interval</i>		<i>Significance</i>	
	<i>Lower</i>	<i>Upper</i>	<i>t</i>	<i>P value</i>
Reformatted panoramic image Para-Sagittal CBCT	-0.24	1.07	1.27	0.21

3) Comparison of implant length choice between modalities:

Tables 13-15 describe the differences in choice of virtual implant length using reformatted panoramic imaging compared with cross-sectional imaging. It shows that using cross-sectional imaging significantly more implants of shorter length were chosen than using reformatted panoramic imaging ($p=0.001$). The most common implant length was 10 mm in each modality (44.3% in reformatted panoramic imaging and 41% in

CBCT imaging). The reformatted panoramic image had 12mm implant (37.7%) as the second choice, whereas CBCT had 8mm implant (36.1%).

Table 13. Comparative choice of implant length decision for each modality.

<i>Implant Length (mm)</i>	<i>Reformatted Panoramic Image</i>	<i>Cross-sectional CBCT Image</i>
	<i>Frequency (Percentage)</i>	<i>Frequency (Percentage)</i>
8mm	11 (18%)	22 (36.1%)
10mm	27 (44.3%)	25 (41%)
12mm	23 (37.7%)	14 (23%)
Total	61	61

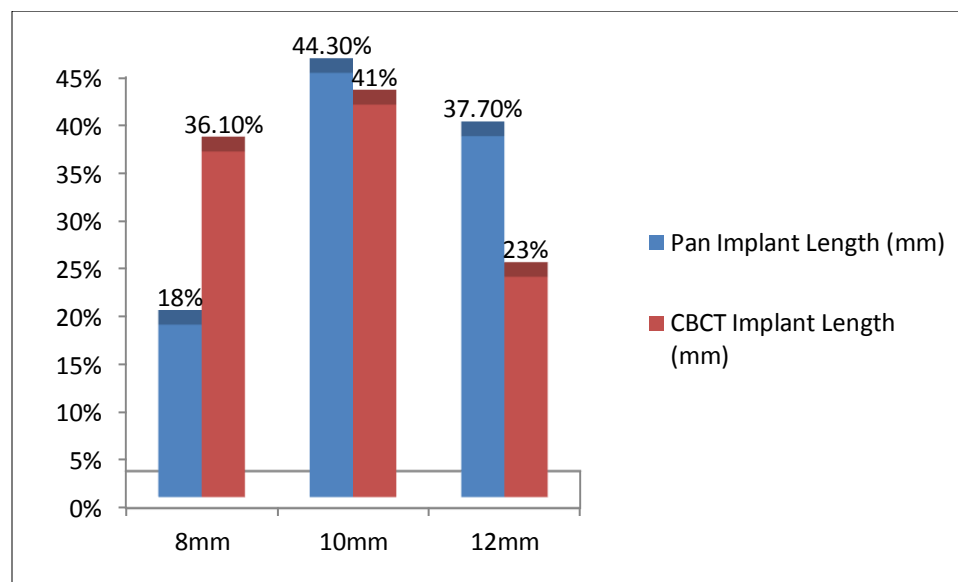


Figure 16. Comparative frequency of choice of Implant length (mm)

Table 14. Comparative cross-tabulated analysis of choice of implant length decision for each modality.

<i>Choice of Implant Length</i>	<i>CBCT Implant Length (mm)</i>			Total
	<i>8mm</i>	<i>10mm</i>	<i>12mm</i>	
PAN-Implant Length (mm) 8mm	10	1	0	11
10mm	11	12	4	27
12mm	1	12	10	23
Total	22	25	14	61

Table 15. Comparative analysis of choice of implant length decision for each modality.

<i>Statistical Test</i>	<i>Value</i>	<i>df</i>	<i>Asymp. Sig. (2-sided)</i>
Pearson Chi-square	26.79	4	0.001
Yates Chi-square	21.28	4	0.001

4) Position of Implant to adjacent anatomic structures – Reformatted panoramic and virtual model

Table 16 shows the relative measurements of Pan Implant in each modality in compared by paired t-Test. The reformatted panoramic imaging mean measurement at implant platform was not significant in mesial aspect and was found 0.10mm less than CBCT imaging ($p=0.26$). It was significant in distal aspect and was 0.54 mm less in reformatted panoramic imaging than CBCT imaging ($p=0.001$). At implant apex, both the mean mesial and distal measurements were found significantly greater in reformatted panoramic imaging than CBCT imaging by 0.22mm ($p=0.04$) and 1.06 mm ($p=0.001$) respectively. Important to note that at implant platform both measurements were less in reformatted panoramic imaging than CBCT, while at implant apex it was the opposite. In

the apical aspect to the implant, the mean distance measurement in reformatted panoramic imaging was 0.17 mm greater than CBCT imaging, but was found not significant ($p=0.42$). The Table 17 shows the angulations measured of Pan implant in reformatted panoramic imaging and CBCT imaging by Paired t-Test. It was found that reformatted panoramic imaging measured the implant angle 1.86° straighter than CBCT imaging, but it was not statistically significant ($p=0.42$).

Table 16. Comparative analysis of virtual implant measurements with adjacent structures for each modality.

<i>Dimension</i>		<i>Modality (Mean ± s.d.)</i>		<i>95% Confidence Interval</i>		<i>Significance</i>		
<i>Implant Location</i>	<i>Site</i>	<i>Reformatted Panoramic Image</i>	<i>Cross-sectional Image</i>	<i>Lower</i>	<i>Upper</i>	<i>t</i>	<i>df</i>	<i>p</i>
Platform	Mesial	3.54 ± 1.09	3.64 ± 1.36	-0.26	0.07	1.13	60	0.26
	Distal	4.67 ± 1.85	5.21 ± 2.47	-0.83	-0.24	3.65	60	0.001
Adjacent Root	Mesial	4.01 ± 1.35	3.79 ± 1.24	0.01	0.41	2.09	60	0.04
	Distal	8.00 ± 3.66	6.94 ± 3.18	0.69	1.41	5.79	60	0.001
Anatomic Structure	Apical	3.70 ± 2.54	3.53 ± 3.04	-0.24	0.56	0.81	60	0.42

Table 17. Comparitive analysis of angulation of virtual implant for each modality.

<i>Modality (Mean ± s.d.)</i>		<i>95% Confidence Interval</i>		<i>Significance</i>		
Reformatted Panoramic Image	Cross-sectional CBCT Image	Lower	Upper	t	df	p
90.62 ± 9.76	88.76 ± 18.81	-2.81	6.53	0.79	60	0.42

5) Exposure of threads of Implant:

Tables 18 and 19 shows the number of exposed threads on the buccal and lingual aspects respectively in each modality. Figure 17-20 shows the percentage of threads exposure in buccal and lingual aspects of each modality. Table 18 showed significantly that the implant placed by viewing reformatted panoramic imaging and virtual 3D model ($M=3.11 \pm 2.58=SD$) had approximately two more threads exposure in buccal aspect than CBCT imaging ($M=0.92 \pm 1.31SD$) ($p=0.001$). Similarly in Table 19, the lingual thread exposure was more in reformatted panoramic imaging ($M=1.51 \pm 2.24SD$) than CBCT imaging ($M=0.11 \pm 0.48=SD$) ($p=0.001$). Fig. 17 shows that the implant placed with reformatted panoramic image and virtual 3D models had as much as 8 implant threads exposed in buccal aspect, whereas, the highest number of threads exposed in buccal aspect was 4 in implants placed with CBCT imaging. CBCT imaging implants had 38 cases with no threads exposure, whereas, the reformatted panoramic imaging and virtual 3D models had only 15 cases. Similarly in Fig. 18, the highest number of threads exposed in lingual aspect of implants placed with reformatted panoramic imaging and virtual 3D models was 8, whereas, the implants placed with CBCT imaging has highest number of 3 threads exposure (less than half). Almost all the cases in CBCT imaging (57) had no threads exposure in lingual aspect compared with (33) cases in reformatted panoramic imaging. This is also reflected in the need for bone grafts in reformatted panoramic

imaging cases more than CBCT imaging in later result section.

Table 18. Comparative analysis showing number of exposed implant threads in buccal aspect for each modality.

Buccal Threads Exposure	Modality (Mean \pm s.d.)		95% Confidence Interval		Significance		
	Reformatted Panoramic Image	Cross-sectional CBCT Image	Lower	Upper	t	df	p
	3.11 \pm 2.58	0.92 \pm 1.31	1.59	2.80	7.25	60	0.001

Table 19. Comparative analysis showing number of exposed implant threads in lingual aspect for each modality.

Lingual Threads Exposure	Modality (Mean \pm s.d.)		95% Confidence Interval		Significance		
	Reformatted Panoramic Image	Cross-sectional CBCT Image	Lower	Upper	t	df	p
	1.51 \pm 2.24	0.11 \pm 0.48	0.84	1.94	5.08	60	0.001

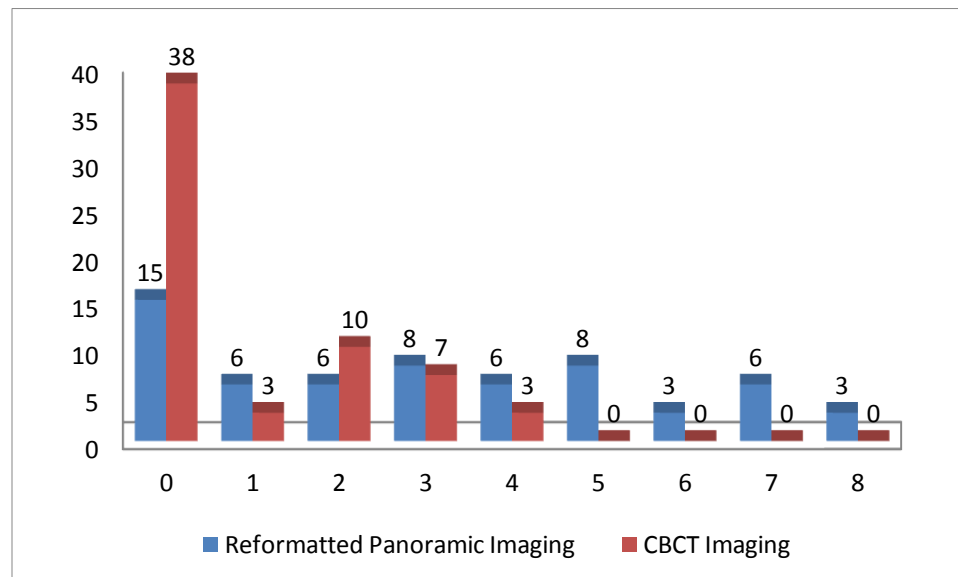


Figure 17. Frequency of exposed implant threads in buccal aspect for each modality.

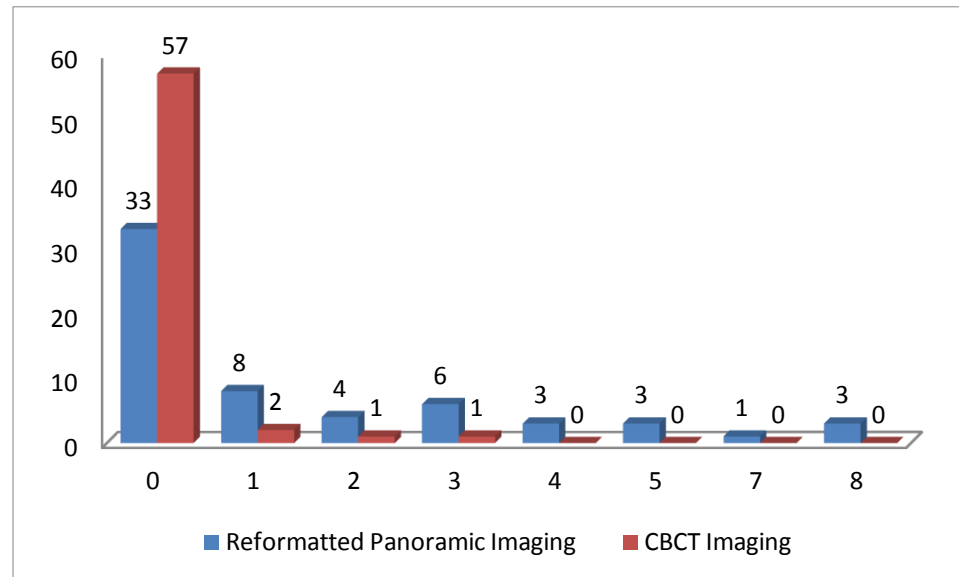


Figure 18. Frequency of exposed implant threads in lingual aspect for each modality.

6) Effect of Modality on Need for Bone Grafting after Virtual implant placement:

Table 20 and Fig. 17 shows the consensus of bone-grafting need between the two modalities. The cross-sectional imaging facilitated virtual implant placement resulted in 78.68% (48) of the cases deemed not to require bone grafting required at the time of implant placement as compared with reformatted panoramic imaging 29.9% (18).

Simultaneous bone graft was recommended in 63.93% (39) of the total cases in reformatted panoramic imaging, whereas, only 21.31% (13) cases were identified as needing simultaneous bone graft in cross-sectional imaging. No cases were identified using cross-sectional imaging that required bone grafting prior implant placement whereas using reformatted panoramic imaging alone, 6.55% (4) of cases were designated as requiring prior bone grafting procedures.

Table 20. Guided Bone Regeneration (GBR) necessity for each modality.

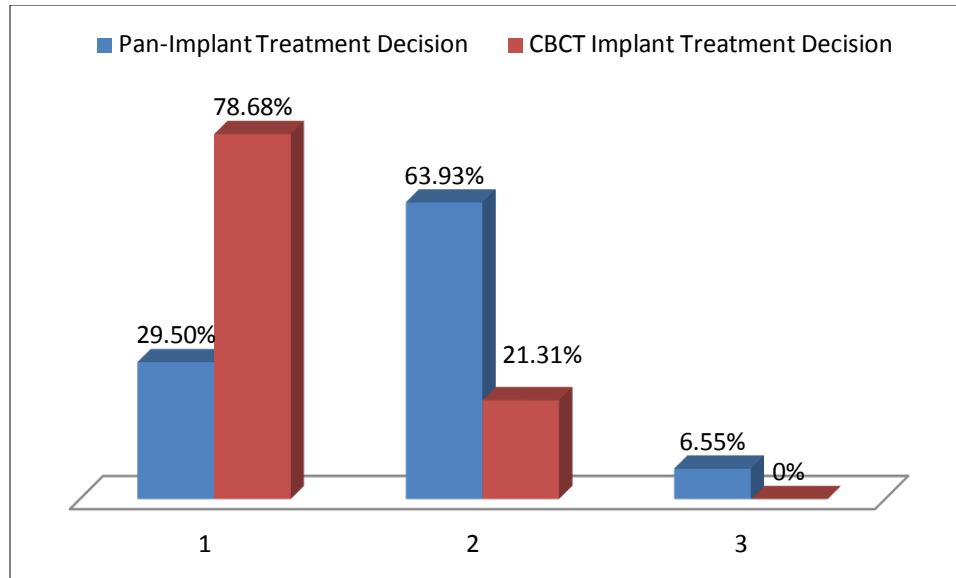
<i>Guided Bone Regeneration</i>	<i>Reformatted Panoramic Image</i>	<i>Cross-Sectional Images</i>	<i>Total</i>
No GBR necessity	18	48	66
GBR necessity	43	13	56
Total	61	61	122

Table 21. Comparative analysis of Guided Bone Regeneration necessity for each modality.

<i>Statistical Test</i>	<i>Value</i>	<i>df</i>	<i>Asymp. Sig. (2-sided)</i>
Pearson Chi-square	29.71	1	0.001
Yates Chi-square	27.76	1	0.001

Table 22. Comparative cross-tabulation of Guided Bone Regeneration each modality

<i>Level of GBR necessity</i>		<i>CBCT Implant</i>		<i>Total</i>
		No GBR necessity	Simultaneous-GBR necessity	
Pan-Implant	No GBR necessity	13	5	18
	Simultaneous-GBR necessity	31	8	39
	Staged-GBR necessity	4	0	4
	Total	48	13	61



*1-No GBR necessity, 2- Simultaneous-GBR necessity 3- Staged-GBR necessity.

Figure 19. Level of Guided Bone Regeneration necessity for each modality

CHAPTER 5

DISCUSSION

Pretreatment bone evaluation and placement planning is an important step in the success of prosthetic implant therapy (Patel 2010, Worthington, *et al.*, 2010). The two broad classification of dental imaging used in dental implant planning are the 2D conventional imaging which includes periapical, occlusal, and panoramic imaging; and the 3D imaging which includes CBCT, MRI and CT. There exists a lack of consensus on the relative clinical efficacy of dental imaging for implant planning. Some authors suggest that the use of conventional panoramic imaging and clinical investigation is adequate for assessment of dental implant treatment planning (Harris, *et al.*, 2002, Dave, *et al.*, 2012). Others suggest that panoramic radiographs in conjunction with periapical radiographs are satisfactorily for the bone volume assessment in anatomical important regions such as the molar region, where the presence of inferior alveolar nerve makes implant placement challenging (Vazquez, *et al.*, 2008). Some clinicians believe that the reluctance in use of CBCT for implant planning is the lack of justifiable reasons for exposing patients to extra amount of radiation when the same clinical outcomes can be achieved at lower radiation dose in panoramic radiography (Frei, *et al.*, 2004). It has also been reported that digital panoramic radiography can accurately determine the pre-operative implant length in premolar and molar mandibular segments (Vazquez, *et al.*, 2013). Kim, *et al.*, (2011) suggest that digital panoramic radiography has a magnification rate which does not affect the accurate assessment of vertical bone height for

preoperative assessment of implant therapy. Current guidelines by various organizations are cautious in supporting the general use of CBCT for dental implants planning. The European Association of Osseointegration (EAO) suggest the use of cross sectional imaging when conventional radiography fails to give adequate information about the anatomical boundaries, so that the damage to vital anatomical structures can be prevented (Harris, *et al.*, 2012). The International Congress of Oral Implantologist (ICOI) suggest CBCT as an imaging alternative to conventional radiography, if it fails to provide regional three-dimensional information (Benavides, *et al.*, 2012). The International Team of Implantology support the use of CBCT for dental implants. They suggested statistically significant clinical research for future guidelines. They also highlighted the lack of standardized methodological approaches when researching the use of CBCT in implant dentistry (Bornstein, *et al.*, 2014). The American Academy of Oral and Maxillofacial Radiology states that cross-sectional imaging should be used for assessment of most dental implant sites and CBCT should be preferably used (Tyndall, *et al.*, 2012). These positions indicate a lack a consensus and therefore there is a strong need for further research in assessing the benefits of cross-sectional imaging in implant dentistry as compared with conventional radiography. Little research has been done comparing restorative space measurements according to the alveolar ridge between conventional imaging and cross-sectional imaging or the effects of imaging modality on the choice of implant length or bone grafting need.

In this study, a sample specifically focusing on edentulous posterior region was selected. The reason for selecting this region was the presence of important anatomical structures which makes the implant planning a critical step. High occlusal forces in this

region make it important that adequate bone volume is present in peri-implant tissues. Occlusal overload causes the bone loss around implant which can lead to implant failure (Fu, *et al.*, 2012, Hsu, *et al.*, 2012). The maxillary posterior region is the most common site for the implant failure because of low bone density (Kim, *et al.*, 2010). The mandibular posterior region has two major anatomical structures which includes inferior alveolar canal containing inferior alveolar nerve and vessels and the lingual concavity, which makes the cases at higher risk of inferior alveolar nerve injury. The lingual concavity in this region serves as a source of bony fenestration in implant placement if poor anatomic information is gathered (Lin, *et al.*, 2014). The presence of the mental foramen makes the posterior region difficult to place implant, where damage to the nerve can lead to paresthesia, dysaesthesia or anesthesia of lower lips or tongue. This condition can persist anywhere from few days, weeks, months or even permanent in some cases (Alghamdi 2013). The cases selected for our research had not more than two missing teeth at implant sites. The specific case selection criteria followed in this study were not observed in previous studies (Correa, *et al.*, 2013, Pedroso, *et al.*, 2013). The software selected in our study to view images was then viewed in InVivo 5.2 by Anatomage[®]. This software was found reliable in CBCT image analysis (Azeredo, *et al.*, 2013). In our study, reformatted panoramic images were used as compared to panoramic radiographs or digital panoramic radiographs. The conventional panoramic radiographs have a distortion and magnification ranging from 10-30% in vertical and horizontal dimensions. The digital panoramic radiography has a magnification and distortion ranging from 4-10%. Digital panoramic radiograph has been studied for dental implant therapy and has been found accurate for dental implant therapy in various studies (Kim, *et al.*, 2011, Vazquez,

et al., 2013). But the diagnostic accuracy of reformatted panoramic images created from cross-sectional imaging was found better than digital panoramic radiographs (Pittayapat, *et al.*, 2013). The reformatted panoramic images were generated from cross-sectional CBCT information by following a specific criterion. The focal trough was created at the level of cementoenamel junction of right 2nd molar. If right 2nd molar was missing, left 2nd molar was used. Reformatted panoramic images was created of 15mm thickness throughout the study. This ensured reproducibility and standardization of all reformatted panoramic images. The ITI treatment guidelines for posterior region were followed for placement of dental implant in alveolar ridge for each modality. The distance between the implants was recommended to be at least 1.0mm-1.5mm in bucco-lingual dimension(Vera, *et al.*, 2012). At least 2mm distance was kept from the inferior alveolar nerve and minimum of 1.5mm of bone in any dimension of dental implant(Kraut, *et al.*, 2002). This position was verified by three experienced Prosthodontists. The bone graft implant treatment decision was made in consensus with three Prosthodontists. This was done to avoid the complex issues of inter-examiner reliability which was missed in previous studies(Correa, *et al.*, 2013). The measurements relative to adjacent structures was measured and compared with the same measurements done in CBCT imaging. No study previously has compared the effect of choice of imaging modality on the need of bone graft treatment decision. In our study the sample was stratified based on jaw groups which was similar in other studies (Correa, *et al.*, 2013, Pedroso, *et al.*, 2013). There were two samples in our study, which were the subject cases (n1=52) and the individual implant sites (n2=61)(Alkhader, *et al.*, 2013).

In the first part of our study we compared the horizontal and vertical restorative

distance between the reformatted panoramic imaging and CBCT imaging. The majority (76.9%) of edentulous region were located in mandible. A total of 82.7% had one missing tooth in the edentulous region. The most common teeth missing in our study were mandibular 1st molar (61.6%). The left 1st molar was missing 38.5% and right 1st molar by 23.1%. Paired t-test was applied between the horizontal and vertical distance relationship in each modality. The correlation showed significant linear relationship between the variables. The mean horizontal coronal restorative space distance was found to be 0.45mm higher in reformatted panoramic images than the axial CBCT images ($p=0.001$). This showed that the best form of panoramic imaging (i.e reformatted panoramic imaging) even has a magnification and distortion factor that results in greater horizontal restorative space measurements. This could be critical information for majority of dentists, who uses panoramic radiography with greater magnification and distortion than reformatted panoramic radiography to assess the horizontal restorative distance. The mean vertical restorative space distance was found 0.42mm higher in reformatted panoramic images than the para-sagittal CBCT images, but this value was not statistically proven.

The most important variable in our study was the choice of implant length. The choice with panoramic imaging and virtual 3D clipped model was compared with decision made after additional CBCT information. The cross-sectional information resulted in the selection of shorter implant than reformatted panoramic images and virtual 3D model ($p=0.001$). The most common implant length selected in each modality was 10mm implant. But reformatted panoramic imaging and virtual 3D model information resulted in selection of 12mm implant in 37.70% of cases. The CBCT information

resulted in 8mm implant length decision in 36.10% of cases. The choice of dental implant length remained unchanged in 50% of the total cases. A total of 11 cases that had 10mm implant length decision in reformatted panoramic imaging were changed to 8mm implant after CBCT information. Similarly, 12 cases with 12mm implant length decision were changed to 10mm implant length decision after addition of CBCT information. Correa, *et al.*, 2013 also found similar results, but the implant length decision was taken by an automated software based on measurements done by three observers(Correa, *et al.*, 2013). The number of threads exposed in buccal and lingual aspects of dental implants was found to be significantly lower when CBCT information was added in implant placement ($p=0.001$). In buccal aspect, 8 numbers of threads was the highest exposure of implants placed from reformatted panoramic images and 3D models as compared to a maximum of 4 threads exposure in CBCT imaging implants. A total of 38 cases out of 61 had no exposure of threads in CBCT imaging. The mean number of threads exposed in buccal aspect by reformatted panoramic imaging and virtual 3D model was 3.11 as compared to only 0.92 in CBCT imaging. Similarly, the number of threads exposed in lingual aspect was significantly lower in CBCT imaging as compared with reformatted panoramic imaging and virtual 3D model($p=0.001$). The mean value for threads exposed in lingual aspect of reformatted panoramic imaging and virtual 3D model was 1.51 as compared to 0.11 in CBCT imaging. Added CBCT information helps place implant with least threads exposure in buccal and lingual directions. This can be attributed to adjustment of implant angle with added information about the anatomy of alveolar bone available. It shows that if implant is placed with reformatted panoramic imaging and virtual 3D model, there is higher anticipation of bone graft ($p=0.001$). A total of 43 cases

out of 61 in reformatted imaging were placed with bone graft anticipation as compared with only 13 in CBCT imaging. A total of 35 bone graft anticipated decision was changed to no bone grafting after additional information from CBCT imaging was provided. The simultaneous bone graft anticipation was reduced to more than 40% in CBCT imaging from reformatted panoramic imaging.

Our study shows that if additional CBCT imaging is present at the pretreatment planning of implant therapy significant morbidity, time and cost of treatment can be reduced. The additional CBCT imaging improves the placement of implant in alveolar ridge by providing accurate information about adjacent anatomical structures. This leads to a shorter implant length decision with no implant threads exposure. The reduction in bone grafting decision can reduce the total time of implant treatment. Panoramic imaging and virtual 3D model which replicates the impression model, tends to give higher measurement values. This can prove critical for implant assessment where inaccurate measurement can easily lead to implant failure. Our study statistically proves that CBCT information should be considered in the pretreatment implant planning in posterior regions for accurate placement of implant.

Further research needs to be done with larger sample size involving multiple centers for data collection. A prospective study design where dental implants are placed in human cadaver jaw is recommended. This later scanned in each modality and compared with the gold standard of real surgical measurements.

CHAPTER 6

CONCLUSION

The maximum horizontal coronal distance measurement is higher in panoramic imaging as compared with CBCT imaging ($p=0.001$). Additional CBCT imaging information changes the implant length decision towards a shorter implant ($p=0.001$). The CBCT imaging helps in placing the dental implants with minimal threads exposure in bucco-lingual aspects by providing adequate bone depth information ($p=0.001$). The need for bone grafting is determined to be lower when cross-sectional information is provided ($p=0.001$).

REFERENCES

- Alghamdi, A. S. (2013). "Pain sensation and postsurgical complications in posterior mandibular implant placement using ridge mapping, panoramic radiography, and infiltration anesthesia." *ISRN Dent* **2013**: 134210.
- Alkhader, M. and M. Hudieb (2013). "Comparison of mesiodistal space measurements of single-implant sites on panoramic and oblique images generated by cone-beam CT." *Surg Radiol Anat*.
- Almog, D. M. and E. M. Heisler (1997). "Computer intuition: guiding scientific research in imaging and oral implantology." *J Dent Res* **76**(10): 1684-1689.
- Angelopoulos, C. and T. Aghaloo (2011). "Imaging technology in implant diagnosis." *Dent Clin North Am* **55**(1): 141-158.
- Azeredo, F., L. M. de Menezes, R. Enciso, A. Weissheimer and R. B. de Oliveira (2013). "Computed gray levels in multislice and cone-beam computed tomography." *Am J Orthod Dentofacial Orthop* **144**(1): 147-155.
- Babbush, C. A. and J. Brokloff (2012). "A single-center retrospective analysis of 1001 consecutively placed NobelActive implants." *Implant Dent* **21**(1): 28-35.
- Benavides, E., H. F. Rios, S. D. Ganz, C.-H. An, R. Resnik, G. T. Reardon, S. J. Feldman, J. K. Mah, D. Hatcher, M.-J. Kim, D.-S. Sohn, A. Palti, M. L. Perel, K. W. M. Judy, C. E. Misch and H.-L. Wang (2012). "Use of Cone Beam Computed Tomography in Implant Dentistry: The International Congress of Oral Implantologists Consensus Report." *Implant Dentistry* **21**(2): 78-86
10.1097/ID.1090b1013e31824885b31824885.
- Bornstein, M. M., B. Al-Nawas, U. Kuchler and A. Tahmaseb (2014). "Consensus Statements and Recommended Clinical Procedures Regarding Contemporary Surgical and Radiographic Techniques in Implant Dentistry." *Int J Oral Maxillofac Implants* **29**(Supplement): 78-82.
- Buchter, A., U. Joos, H. P. Wiesmann, L. Seper and U. Meyer (2006). "Biological and biomechanical evaluation of interface reaction at conical screw-type implants." *Head Face Med* **2**: 5.
- Correa, L. R., R. Spin-Neto, A. Stavropoulos, L. Schropp, H. E. da Silveira and A. Wenzel (2013). "Planning of dental implant size with digital panoramic radiographs, CBCT-generated panoramic images, and CBCT cross-sectional images." *Clin Oral Implants Res*.
- Dave, M., J. Davies, R. Wilson and R. Palmer (2012). "A comparison of cone beam computed tomography and conventional periapical radiography at detecting peri-implant bone defects." *Clin Oral Implants Res*.
- Esposito, M., G. Cannizarro, E. Soardi, G. Pellegrino, R. Pistilli and P. Felice (2011). "A 3-year post-loading report of a randomised controlled trial on the rehabilitation of posterior atrophic mandibles: short implants or longer implants in vertically augmented bone?" *Eur J Oral Implantol* **4**(4): 301-311.

- Frederiksen, N. L. (1995). "Diagnostic imaging in dental implantology." Oral Surg Oral Med Oral Pathol Oral Radiol Endod **80**(5): 540-554.
- Frei, C., D. Buser and K. Dula (2004). "Study on the necessity for cross-section imaging of the posterior mandible for treatment planning of standard cases in implant dentistry." Clin Oral Implants Res **15**(4): 490-497.
- Fu, J. H., Y. T. Hsu and H. L. Wang (2012). "Identifying occlusal overload and how to deal with it to avoid marginal bone loss around implants." Eur J Oral Implantol **5 Suppl**: S91-103.
- Ganz, S. D. (2008). "Defining new paradigms for assessment of implant receptor sites. The use of CT/CBCT and interactive virtual treatment planning for congenitally missing lateral incisors." Compend Contin Educ Dent **29**(5): 256-258, 260-252, 264-257; quiz 268, 278.
- Garg, A. K. and A. Vicari (1995). "Radiographic modalities for diagnosis and treatment planning in implant dentistry." Implant Soc **5**(5): 7-11.
- Greenstein, G. and D. Tarnow (2006). "The mental foramen and nerve: clinical and anatomical factors related to dental implant placement: a literature review." J Periodontol **77**(12): 1933-1943.
- Harris, D., D. Buser, K. Dula, K. Grondahl, D. Haris, R. Jacobs, U. Lekholm, R. Nakielny, D. van Steenberghe, P. van der Stelt and O. European Association for (2002). "E.A.O. guidelines fo the use of diagnostic imaging in implant dentistry. A consensus workshop organized by the European Association for Osseointegration in Trinity College Dublin." Clin Oral Implants Res **13**(5): 566-570.
- Harris, D., K. Horner, K. Grondahl, R. Jacobs, E. Helmrot, G. I. Benic, M. M. Bornstein, A. Dawood and M. Quirynen (2012). "E.A.O. guidelines for the use of diagnostic imaging in implant dentistry 2011. A consensus workshop organized by the European Association for Osseointegration at the Medical University of Warsaw." Clin Oral Implants Res.
- Hsu, Y. T., J. H. Fu, K. Al-Hezaimi and H. L. Wang (2012). "Biomechanical implant treatment complications: a systematic review of clinical studies of implants with at least 1 year of functional loading." Int J Oral Maxillofac Implants **27**(4): 894-904.
- Kim, Y. K., S. G. Kim, P. Y. Yun, J. W. Hwang and M. K. Son (2010). "Prognosis of single molar implants: a retrospective study." Int J Periodontics Restorative Dent **30**(4): 401-407.
- Kim, Y. K., J. Y. Park, S. G. Kim, J. S. Kim and J. D. Kim (2011). "Magnification rate of digital panoramic radiographs and its effectiveness for pre-operative assessment of dental implants." Dentomaxillofac Radiol **40**(2): 76-83.
- Kraut, R. A. and O. Chahal (2002). "Management of patients with trigeminal nerve injuries after mandibular implant placement." J Am Dent Assoc **133**(10): 1351-1354.
- Krennmair, G., E. Piehslinger and H. Wagner (2003). "Status of teeth adjacent to single-tooth implants." Int J Prosthodont **16**(5): 524-528.
- Lee, J. Y., H. J. Park, J. E. Kim, Y. G. Choi, Y. S. Kim, J. B. Huh and S. W. Shin (2011). "A 5-year retrospective clinical study of the Dentium implants." J Adv Prosthodont **3**(4): 229-235.
- Levin, B. P. (2011). "Horizontal alveolar ridge augmentation: the importance of space maintenance." Compend Contin Educ Dent **32**(8): 12-16, 18-21; quiz 22, 34.
- Lin, M. H., L. P. Mau, D. L. Cochran, Y. S. Shieh, P. H. Huang and R. Y. Huang (2014).

- "Risk assessment of inferior alveolar nerve injury for immediate implant placement in the posterior mandible: A virtual implant placement study." *J Dent* **42**(3): 263-270.
- Misch, C. E., F. Misch-Dietsh, J. Silc, E. Barboza, L. J. Cianciola and C. Kazor (2008). "Posterior implant single-tooth replacement and status of adjacent teeth during a 10-year period: a retrospective report." *J Periodontol* **79**(12): 2378-2382.
- Oliver, R. (2012). "Flapless dental implant surgery may improve hard and soft tissue outcomes." *J Evid Based Dent Pract* **12**(3 Suppl): 87-88.
- Patel, N. (2010). "Integrating three-dimensional digital technologies for comprehensive implant dentistry." *J Am Dent Assoc* **141** Suppl 2: 20S-24S.
- Pedroso, L. A., R. R. Garcia, J. L. Leles, C. R. Leles and M. A. Silva (2013). "Impact of cone-beam computed tomography on implant planning and on prediction of implant size." *Braz Oral Res* **28**(1): 46-53.
- Pittayapat, P., D. Galiti, Y. Huang, K. Dreesen, M. Schreurs, P. C. Souza, I. R. Rubira-Bullen, F. H. Westphalen, R. Pauwels, G. Kalema, G. Willems and R. Jacobs (2013). "An in vitro comparison of subjective image quality of panoramic views acquired via 2D or 3D imaging." *Clin Oral Investig* **17**(1): 293-300.
- Rossetti, P. H., W. C. Bonachela and L. M. Rossetti (2010). "Relevant anatomic and biomechanical studies for implant possibilities on the atrophic maxilla: critical appraisal and literature review." *J Prosthodont* **19**(6): 449-457.
- Rugani, P., B. Kirnbauer, G. V. Arnetzl and N. Jakse (2009). "Cone beam computerized tomography: basics for digital planning in oral surgery and implantology." *Int J Comput Dent* **12**(2): 131-145.
- Saavedra-Abril, J. A., C. Balhen-Martin, K. Zaragoza-Velasco, E. T. Kimura-Hayama, S. Saavedra and M. E. Stoopen (2010). "Dental multisection CT for the placement of oral implants: technique and applications." *Radiographics* **30**(7): 1975-1991.
- Scarfe, W., A. Farman and J. Ruskin (2012). "Is Cone Beam Computed Tomography really necessary for performing Dental Implant Surgery." *Forum Implantologicum* **8**(1): 10.
- Searson, L. and N. Meredith (1997). "The role of implants in restorative dentistry: prosthesis design and aesthetic considerations." *Dent Update* **24**(9): 388-390.
- Sirin, Y., S. Horasan, D. Yaman, C. Basegmez, C. Tanyel, A. Aral and K. Guven (2012). "Detection of crestal radiolucencies around dental implants: an in vitro experimental study." *J Oral Maxillofac Surg* **70**(7): 1540-1550.
- Tyndall, D. A. and S. L. Brooks (2000). "Selection criteria for dental implant site imaging: a position paper of the American Academy of Oral and Maxillofacial radiology." *Oral Surg Oral Med Oral Pathol Oral Radiol Endod* **89**(5): 630-637.
- Tyndall, D. A., J. B. Price, S. Tetradis, S. D. Ganz, C. Hildebolt and W. C. Scarfe (2012). "Position statement of the American Academy of Oral and Maxillofacial Radiology on selection criteria for the use of radiology in dental implantology with emphasis on cone beam computed tomography." *Oral Surg Oral Med Oral Pathol Oral Radiol* **113**(6): 817-826.
- Vazquez, L., Y. Nizam Al Din, U. Christoph Belser, C. Combescure and J. P. Bernard (2011). "Reliability of the vertical magnification factor on panoramic radiographs: clinical implications for posterior mandibular implants." *Clin Oral Implants Res* **22**(12): 1420-1425.
- Vazquez, L., Y. Nizamaldin, C. Combescure, R. Nedir, M. Bischof, D. M. Dohan

- Ehrenfest, J. P. Carrel and U. C. Belser (2013). "Accuracy of vertical height measurements on direct digital panoramic radiographs using posterior mandibular implants and metal balls as reference objects." Dentomaxillofac Radiol **42**(2): 20110429.
- Vazquez, L., N. Saulacic, U. Belser and J. P. Bernard (2008). "Efficacy of panoramic radiographs in the preoperative planning of posterior mandibular implants: a prospective clinical study of 1527 consecutively treated patients." Clin Oral Implants Res **19**(1): 81-85.
- Vera, C., I. J. De Kok, D. Reinhold, P. Limpiphitanakorn, A. K. Yap, D. Tyndall and L. F. Cooper (2012). "Evaluation of buccal alveolar bone dimension of maxillary anterior and premolar teeth: a cone beam computed tomography investigation." Int J Oral Maxillofac Implants **27**(6): 1514-1519.
- Worthington, P., J. Rubenstein and D. C. Hatcher (2010). "The role of cone-beam computed tomography in the planning and placement of implants." J Am Dent Assoc **141 Suppl 3**: 19S-24S.

CURRICULUM VITA

Name: Moiz Ahmad Khan

Address: 619 Montana Ave, Louisville, KY, 40208

DOB: 20th November, 1987

EDUCATION AND TRAINING:

MS Oral Biology

University of Louisville, USA

2012-2014.

BDS Dentistry

University of Karachi, Pakistan.

2006-2010

WORK EXPERIENCE:

Dental Lecturer

Operative Dentistry, Liaquat College of Medicine and Dentistry

2011-2012

Dental House Officer

Karachi Medical & Dental College 2010-2011